

LECTURE 9: HERPESVIRIDAE II

Russ Fraser, Fall 2023

Housekeeping

- Questions from last time?



Bovine herpesviruses

Bovine herpesviruses (page 110)

- Infectious bovine rhinotracheitis (IBR) virus (BHV-1)
- Bovine mammilitis virus (BHV-2)
- BHV-5
  - Previously classified as BHV-1 subtype 3 or BHV-1.3
  - Also called Bovine encephalitis herpesvirus
  - Causes encephalitis in neonatal and young calves; disease is associated with 50% mortality (it is a rule out for CNS disease in calves).

BHV-1: general

- Host range:
  - **cattle**, goats, & pigs.

- Causes a variety of syndromes of varying severity
  - Respiratory disease (infectious bovine rhinotracheitis)
    - BHV1.1 and BHV1.2a
  - Venereal disease (infectious pustular vulvovaginitis and balanoposthitis)
    - BHV1.2b
  - Severe GI disease in neonatal calves
  - Abortion

Rarely occur together or in the same herd

- Virus establishes latency in trigeminal & sciatic ganglia.

- Especially important in feedlots & intensive dairies

- Key part of shipping fever/respiratory disease complex



This Photo by Unknown Author is licensed under CC BY-SA

BHV-1: transmission

- Transmission:
  - Direct contact (especially under crowded conditions)
  - Aerosol
  - Venereal transmission (natural or AI)



BHV-1

IBR

Infectious bovine rhinotracheitis

IPV

Infectious pustular vulvovaginitis

BHV-1 (IBR): pathogenesis

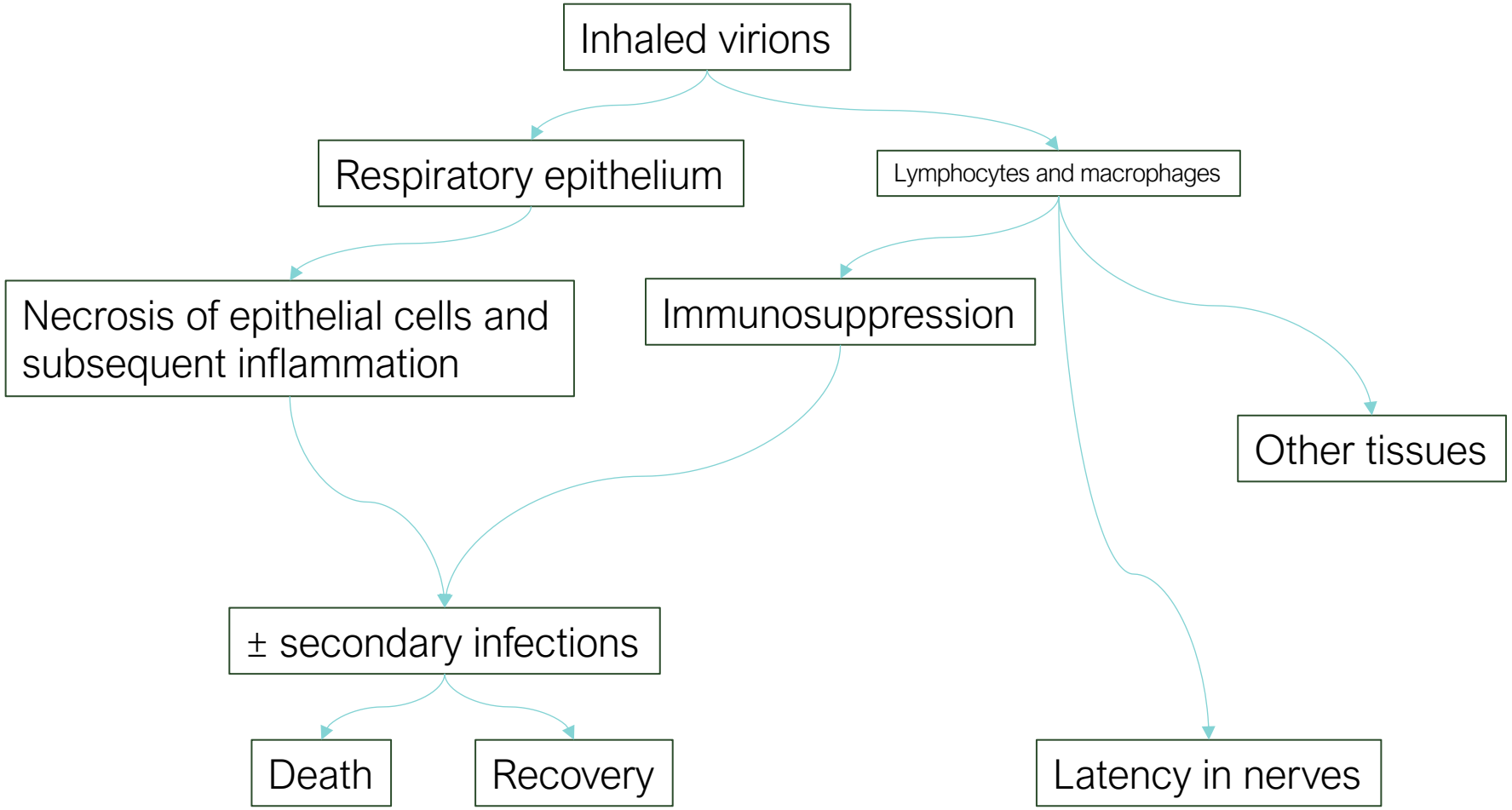

BHV-1 (IBR): clinical signs

- Vary according to a number factors, including age, immune status, environment, genetics, infecting dose, etc.

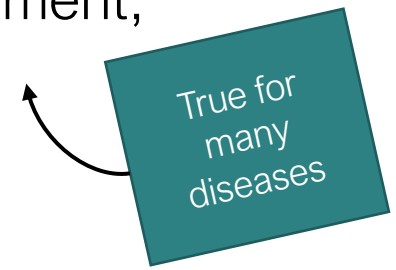

- In adults
  - Fever, anorexia, ↓ milk production, ↑ nasal d/c, ↑ RR
  - ↑ lung sounds on auscultation
  - ± mucosal erosions and ulcers
  - ± conjunctivitis (sometimes the only symptom noted)
  - ± abortion (with or w/out respiratory signs, as long as 100 days after initial infection)
  - Rarely fatal
- Often more severe in young calves
  - Significant bronchopneumonia
  - May be fatal
- Neonates
  - Acute respiratory and ulcerative gastroenteritis, with inflammation and necrosis of the soft palate
  - Often fatal

BHV-1 (IBR): gross lesions

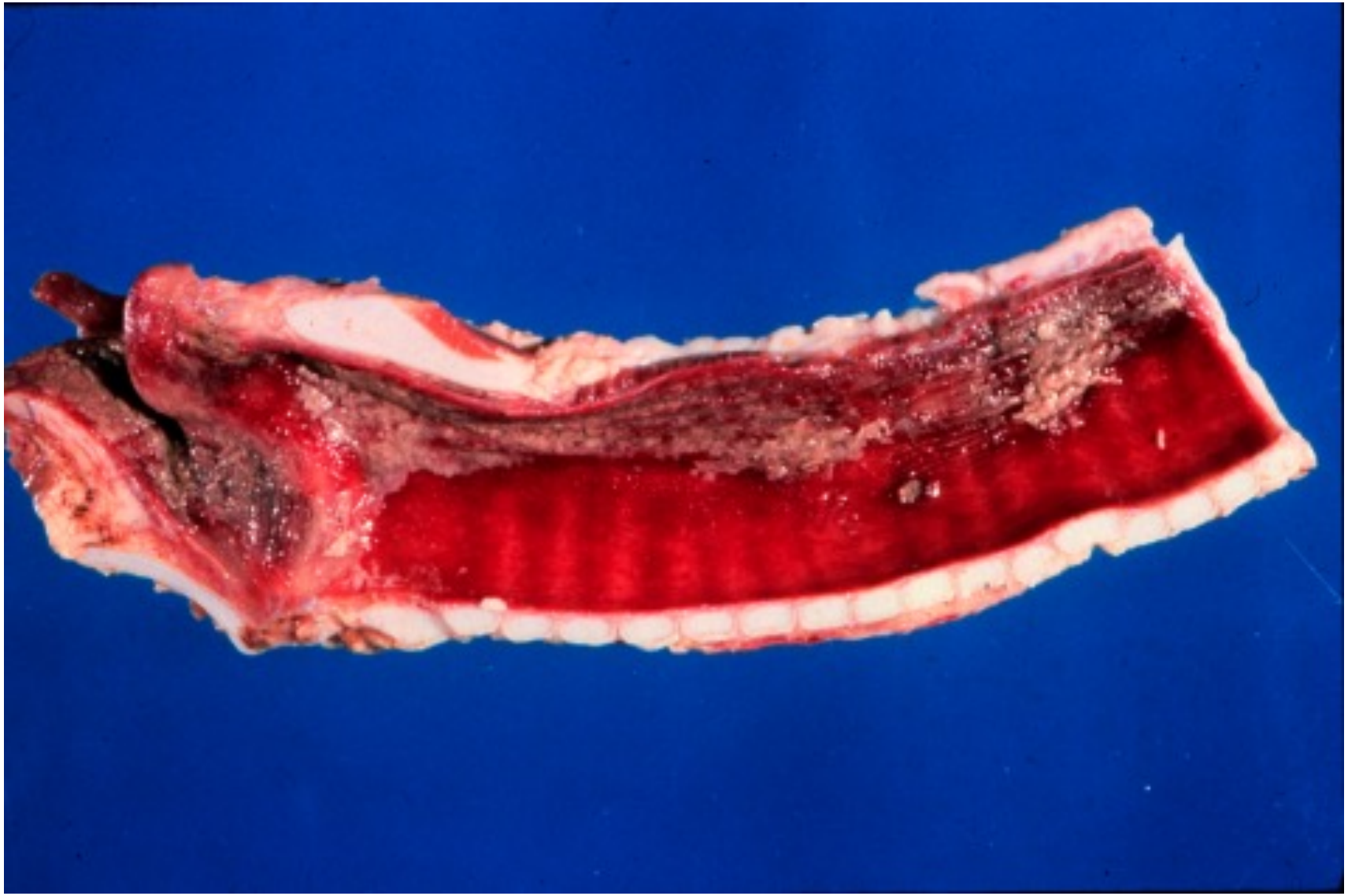

BHV-1 (IBR): gross lesions



BHV-1 (IBR): gross lesions



BHV-1

IBR

Infectious bovine rhinotracheitis

IPV

Infectious pustular vulvovaginitis

BHV-1 (IPV): Clinical signs

- Most common in dairy cattle
- Often stand apart from herdmates
- Tail held away from contact with vulva
- Many cases are subclinical



BHV-1 (IPV): clinical signs and gross

- Subclinical → severe
- Fever, anorexia
- Polyuria and pollakiuria
- Swollen vulva, vulvar discharge, numerous pustules
- Similar findings in bulls (but on their penis)
  - Semen may be contaminated
- Mortality is rare
- Abortion is rare



BHV-1 (IPV): clinical signs and gross

- Subclinical → severe
- Fever, anorexia
- Polyuria and pollakiuria
- Swollen vulva, vulvar discharge, numerous pustules
- Similar findings in bulls (but on their penis)
  - Semen may be contaminated
- Mortality is rare
- Abortion is rare



BHV-1: diagnosis and control

- Clinical signs → suspicious
- PCR on nasal or conjunctival swabs
  - Also virus isolation, EM, etc.
- MLV and inactivated vaccines are available and widely used
  - MLV may → latent, though modern vaccines have addressed this
- Vaccination helps prevent/reduce disease, but does not prevent infection or shedding

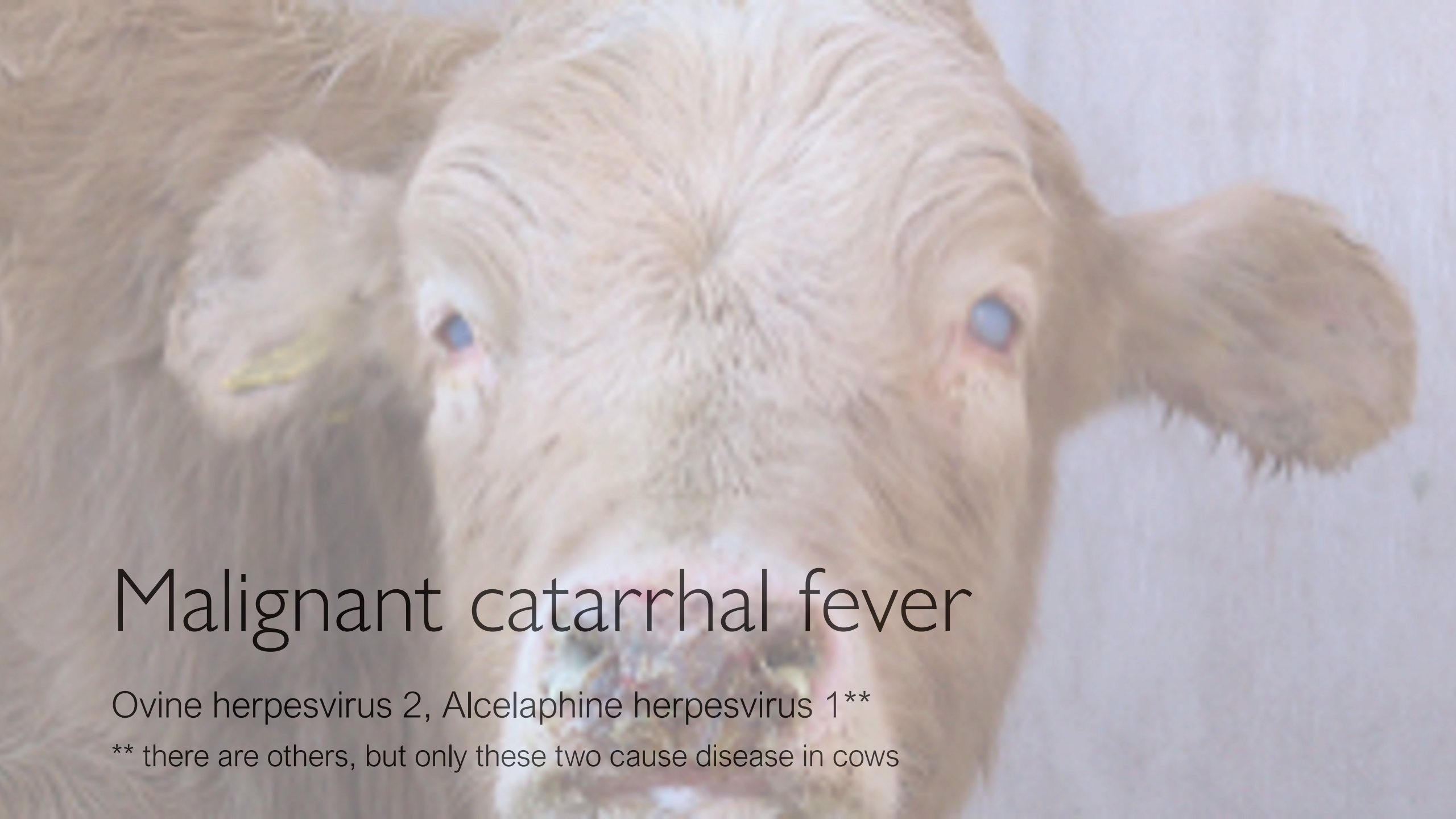

Malignant catarrhal fever

Ovine herpesvirus 2, Alcelaphine herpesvirus 1**

** there are others, but only these two cause disease in cows

OvHV-2 (SA-MCF): general

- DOES NOT cause disease in the natural host, sheep and goats.
  - Is a latent and subclinical infection.
  - Unpredictably shed only by animals > 5 months old

- KILLS cows (~100%)
  - And deer, bison, antelope, giraffes, rarely swine
  - NOT transmitted between cattle – they are dead-end hosts.

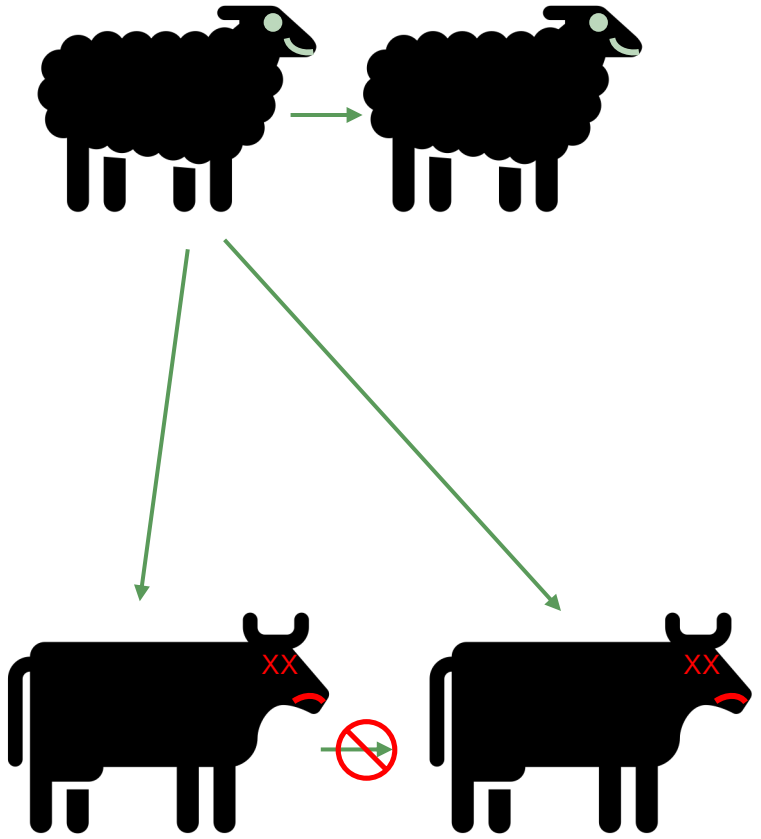

OvHV-2 (SA-MCF): transmission

- Aerosolized nasal secretions containing virions from nearby sheep
  - 94-99 % of sheep in NA have virus
- Direct contact
- High infective dose seems to be required

OvHV-2 (SA-MCF): pathogenesis

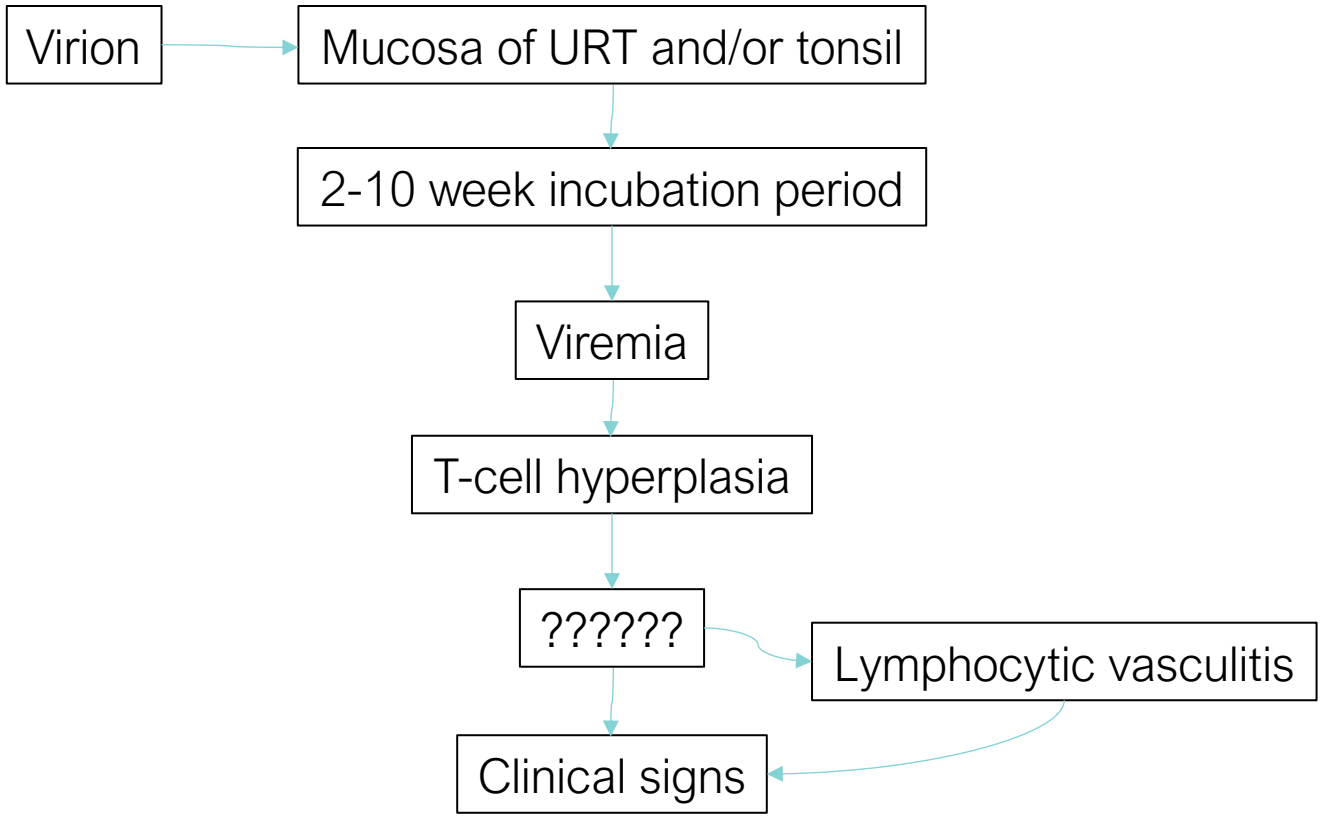

OvHV-2 (MCF): clinical signs

- Vary significantly
- Lymphadenopathy is consistent
- Fever
- Oral and GI erosions/ulcers
- Diarrhea
- Mucopurulent nasal d/c
- Conjunctivitis
- Corneal edema
- More…

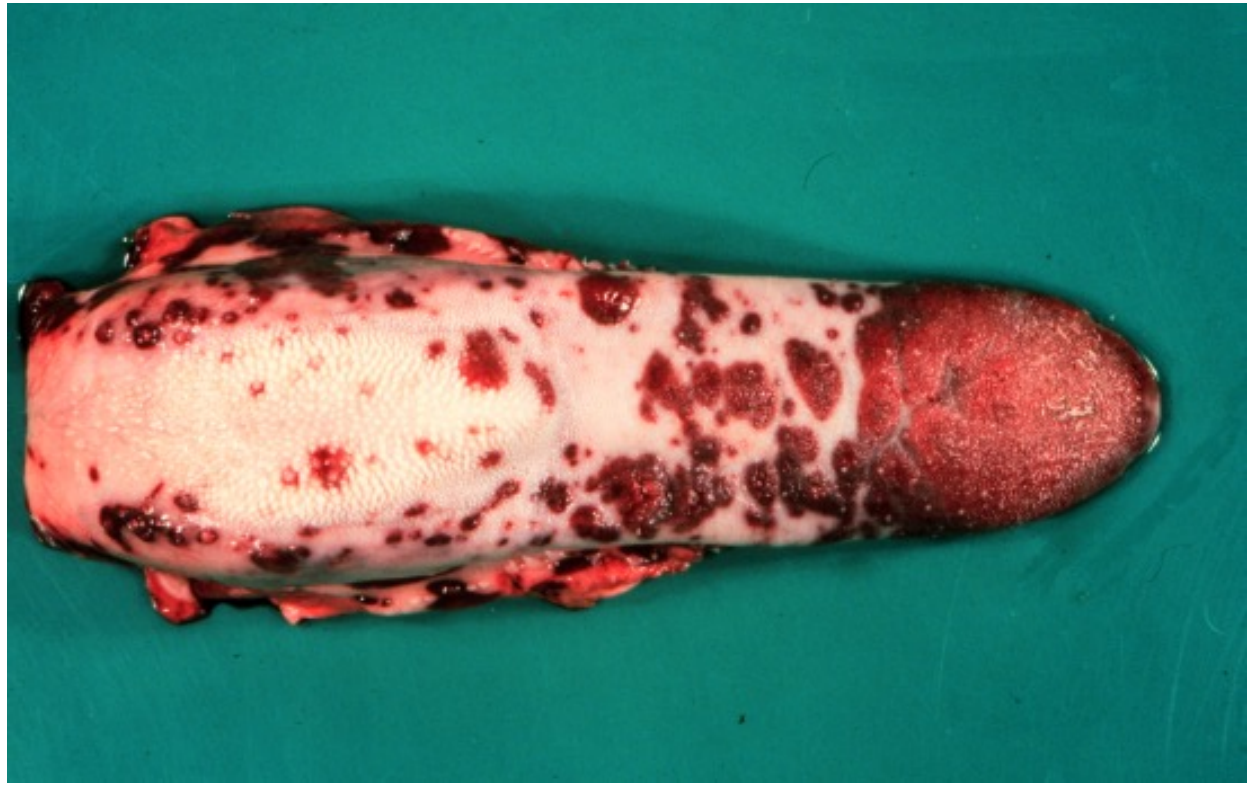

OvHV-2 (MCF): clinical signs

- Vary significantly
- Lymphadenopathy is consistent
- Fever
- Oral and GI erosions/ulcers
- Diarrhea
- Mucopurulent nasal d/c
- Conjunctivitis
- Corneal edema
- More…

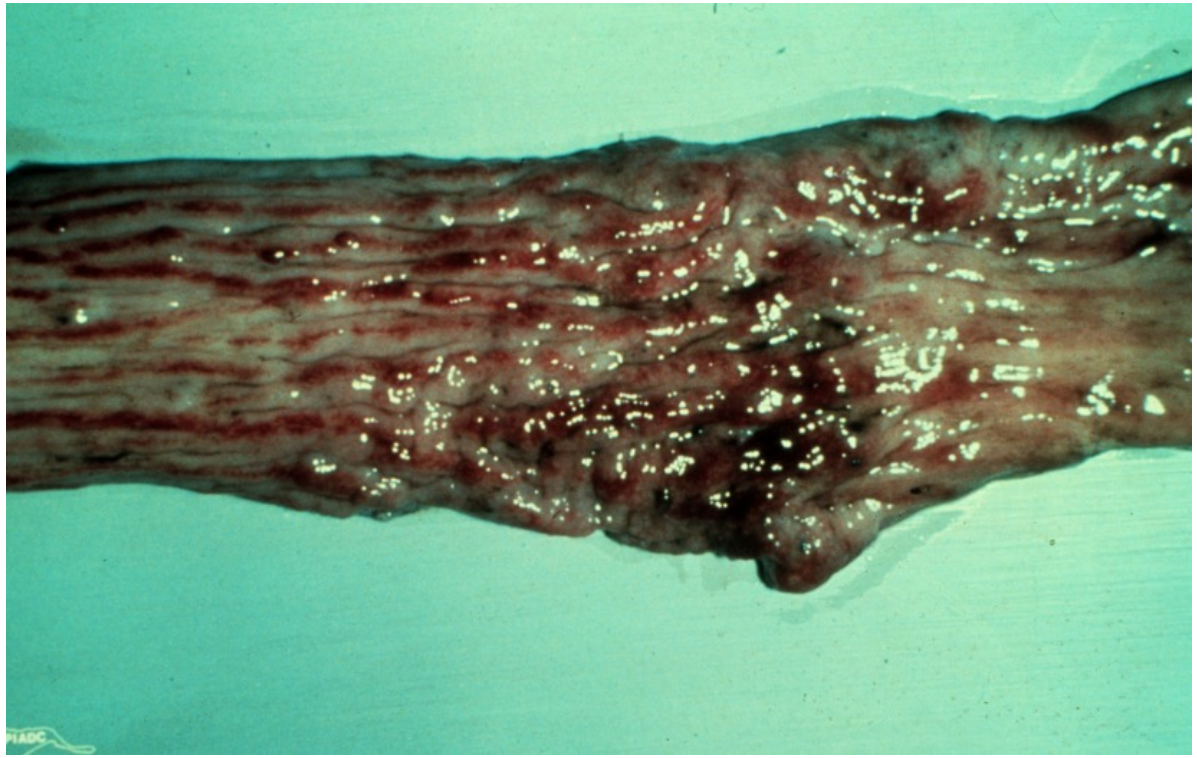

OvHV-2 (MCF): clinical signs

- Vary significantly
- Lymphadenopathy is consistent
- Fever
- Oral and GI erosions/ulcers
- Diarrhea
- Mucopurulent nasal d/c
- Conjunctivitis
- Corneal edema
- More…



OvHV-2 (MCF): clinical signs

- Vary significantly
- Lymphadenopathy is consistent
- Fever
- Oral and GI erosions/ulcers
- Diarrhea
- Mucopurulent nasal d/c
- Conjunctivitis
- Corneal edema
- More…



OvHV-2 (SA-MCF): diagnosis

- Diagnosis:
  - Suspect MCF on basis of clinical signs and history of contact w/ sheep
  - PCR, serology
  - Histopath showing widespread vasculitis is very, very suspicious (almost pathognomonic)

- Differential diagnosis:
  - BVDV, BVH-1, (FMDV, VS, rinderpest, bluetongue), photosensitization (& Yersiniosis in deer).

- Control:
  - No vaccine available
  - Keep cattle separate (1/4 mile apart) from carrier sheep or wildebeest.



Canine herpesvirus-1

CHV-1: general

- Probably present worldwide; prevalence estimated at 20 %
  - Disease is relatively rare.
- Causes hemorrhagic disease of puppies
- Only affects Canidae.
- Standard herpesvirus:
  - Latent in nerves
- Disease is most severe (fatal) in young puppies (< 2-3 weeks of age)
- Older animals may show respiratory symptoms or reproductive lesions
  - May be subclinical

CHV-1: pathogenesis

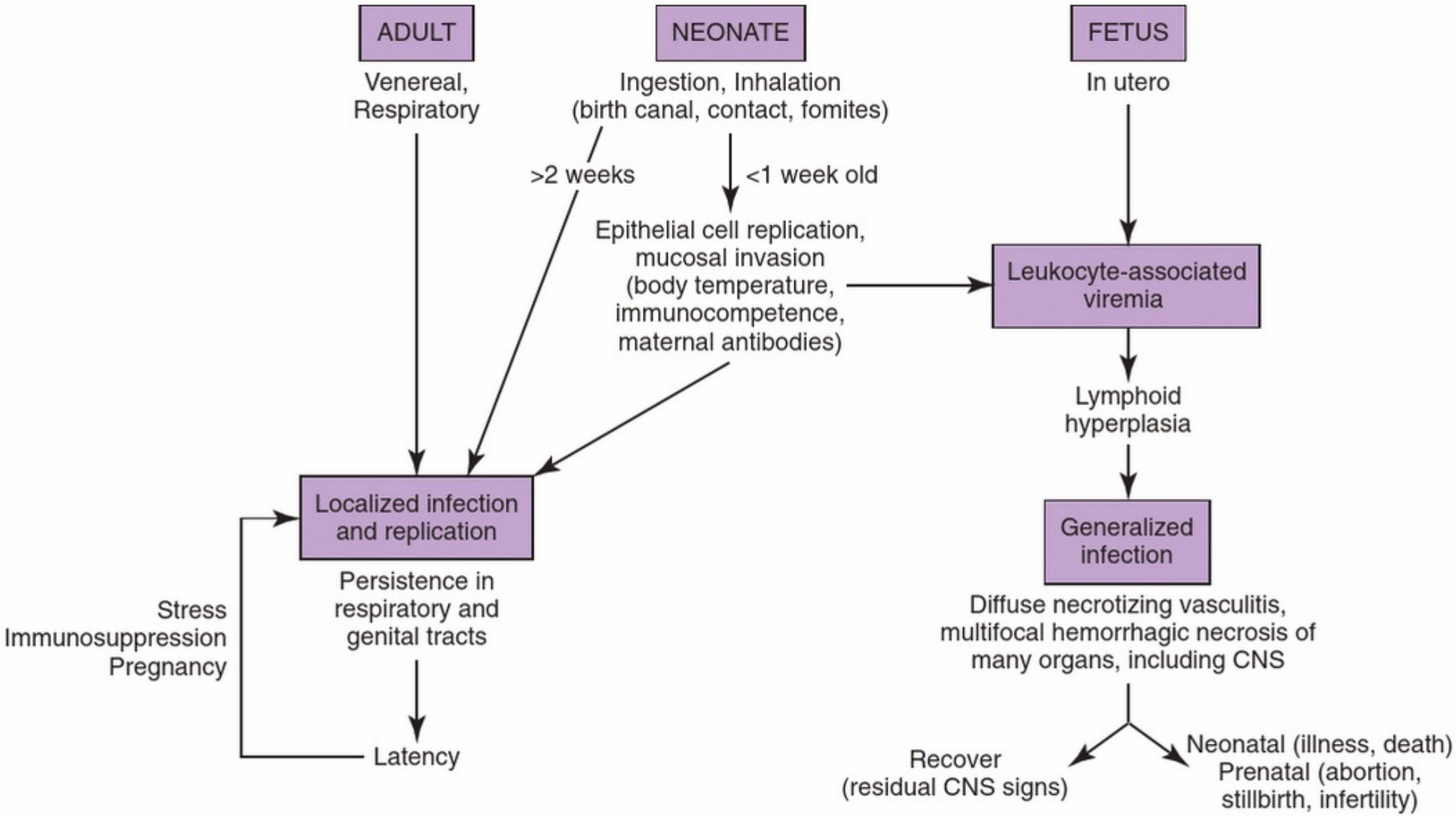

FIG. 5-2 Pathogenesis of CHV infection.

CHV-1: clinical signs

- Pregnant bitches:
  - abortion, stillborn runted pups
  - Neonatal deaths in puppies <1 week old.

- Puppies infected 1-3 wks of age:
  - Yellow-green feces
  - Laboured breathing
  - Incessant crying
  - Hemorrhages on mucus membranes
  - Sudden death is possible

- Older dogs:
  - Subclinical
  - ± respiratory disease
  - ± genital disease.



CHV-1: lesions and diagnosis

- Pathology:
  - Hemorrhages & focal necrosis of all organs, especially kidney
  - Intranuclear inclusion bodies in kidney
  - Lymphoid depletion

- Diagnosis:
  - Confirmatory diagnosis:
    - PCR, fluorescent Ab on affected tissues



Noah's Arkive F29872

CHV-1: treatment and control

- Supportive care
- Acyclovir has been used (but long-term CNS and myocardial damage may still occur)

- No vaccine available in North America
  - One is available in Europe





Feline herpesvirus-1

Rhinotracheitis, ‘rhino’

http://www.abcdcatsvets.org/feline-herpesvirus

Feline herpesvirus 1 (FVR): general

- Widespread, with most cats exposed at some point
- Highly susceptible to common disinfectants
  - Only lives for ~ 18 hours in the environment
- The vast majority of recovered cats will become latent carriers
- Is a key component of feline upper respiratory disease

FHV-1: transmission

- Acutely ill animals shed large amounts of virus
- Latent animals also contribute, but to a lesser degree
- Direct contact is most important, but aerosol may also play a role
  - Indirect transmission is a risk only in high density enviros – shelter, cattery
- Virus enters through the nasal, oral, or conjunctival route, and replicates in the epithelium

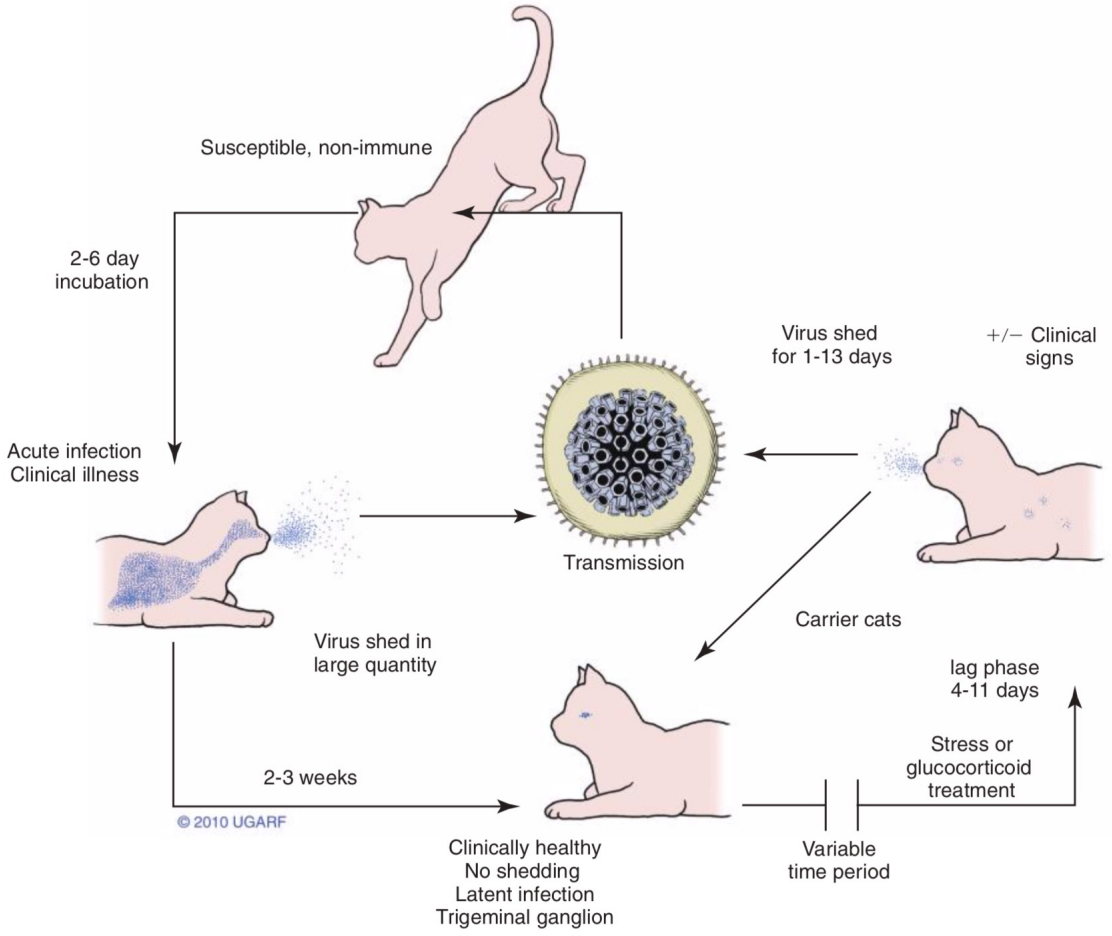

FHV-1: clinical signs

Most signs are related to viral induced necrosis of epithelium and subsequent inflammation (mostly neutrophilic)

- Depression, sneezing, anorexia, pyrexia
- Sneezing & ocular d/c (serous → mucopurulent)
- Corneal ulcers
- Usually resolves in 10-20 days
- In serious cases: severe damage to turbinates and mucosa can lead to ↑ susceptibility to bacterial infections
- Acute infection in young kittens or immunosuppressed can → death



FIG. 14-4 Kitten with FHV-1 infection showing mucopurulent discharges typical of the later stages of the disease. (Courtesy Susan Dawson, University of Liverpool.)

Greene's Infectious Disease of the Dog and Cat

FHV-1: clinical signs

Most signs are related to viral induced necrosis of epithelium and subsequent inflammation (mostly neutrophilic)

- Depression, sneezing, anorexia, pyrexia
- Sneezing & ocular d/c (serous → mucopurulent)
- Corneal ulcers
- Usually resolves in 10-20 days
- In serious cases: severe damage to turbinates and mucosa can lead to ↑ susceptibility to bacterial infections
- Acute infection in young kittens or immunosuppressed can → death



FIG. 14-5 Cat with ulcerative keratitis caused by FHV-1 infection. (Courtesy Susan Dawson, University of Liverpool.)

Greene's Infectious Disease of the Dog and Cat

FHV-1: diagnosis

- The diagnosis is often based on clinical signs alone.

- Differential diagnosis includes:
  - Feline calicivirus
  - Bordatella bronchiseptica
  - Chlamydia felis (conjunctivitis)

- Confirm diagnosis by
  - PCR or virus isolation on oral swabs
  - Serology (seroconversion)

TABLE 14-1

Essential Features of Clinical Respiratory Disease[a] Related to the Pathogen Involved

Feature	FHV-1	FCV[b]	Bb	ChF
Lethargy	+++	+	+	+
Sneezing	+++	+	++	+
Conjunctivitis	++	+	–	+++[c]
Hypersalivation	++	–[d]	–	–
Ocular discharge	+++	+	(+)	+++
Nasal discharge	+++	+	++	+
Oral ulceration	(+)	+++	–	–
Keratitis	+	–	–	–
Coughing	(+)	–	++	–
Pneumonia	(+)	(+)	+	+/–
Lameness	–	+	–	–

+++, Marked; ++, moderate; +, mild; (+), less common; +/–, subclinical; –, absent; *Bb, Bordetella bronchiseptica; ChF, Chlamydophila felis*; *FCV*, feline calicivirus; *FHV-1*, feline herpesvirus.
[a]For FCV-associated virulent systemic disease signs, see text.
[b]Strain variation.
[c]Often persistent.
[d]Slight wetness may be seen around the mouth if ulcers present.
Adapted from Ref. 50. Used with permission.

Greene's Infectious Disease of the Dog and Cat

FHV-1: treatment and control

- The majority of cases will recover with supportive care

- Treatment:
  - Acyclovir & idoxyuridine eye drops (amongst others) for corneal ulcers.
  - L-Lysine – jury is still out.

- Control:
  - Vaccination with MLV virus – FHV-1 is a core vaccine
    - Prevents disease, not necessarily infection
    - You should still vaccinate animals that have recovered from FHV-1
  - Good husbandry, especially in stressful environments.



Suid (porcine) herpesvirus-1

Pseudorabies, Aujeszky's disease, "mad itch"

SuHV-1 (Pseudorabies): general

- Causes Aujeszky's disease in pigs.

- Disease is exotic and reportable in Canada
  - In USA, virus is endemic in feral swine
    - Commercial herds are free
  - Virus is widespread in Europe, Asia & South America.

- Host range is unusually wide for a herpesvirus
  - Pigs are the natural host and reservoirs of the virus
  - Most mammals (**rarely horse**) are susceptible & are sporadically affected resulting in death & no virus excretion or latency

SuHV-1 (Pseudorabies): transmission

- Pig-to-pig:
  - Mainly direct respiratory and nose-to-nose contact
  - Indirect transmission through contaminated clothing, footwear, water troughs, etc
  - Vertical transmission also occurs
  - Latent pigs are an important source of virus

- Pig-to-other-species
  - Contaminated meat – either pig, or rat that has become infected (cats, dogs)
  - Direct contact with pig

SuHV-1 (Pseudorabies): pathogenesis

- Oral infection → cranial nerves → axonal transport to brain → clinical signs → death or latency

- Viremia cannot be demonstrated

SuHV-1 (Pseudorabies): clinical signs

	Piglets	• Inability to move or stand d/t posterior paralysis. • fever, loss of appetite, vomiting • Incoordination, convulsions and paralysis. • Mortality in suckling pigs is close to 100 %
	Weaner pigs	• Mortality rate 5-10 % • Clinical signs resemble those in suckling pigs but respiratory signs including coughing, sneezing and laboured breathing, are more prominent.
	Grower/finishers	• Respiratory disease is the most common sign • Neuro signs may also occur (convulsions) • Mortality rate 1-2 %
	Adults	• Often mild or unapparent. • Early embryonic mortality, abortion, mummified fetuses, stillbirths or they could give birth to weak and trembling pigs who quickly die

SuHV-1 (Pseudorabies): lesions

- Few gross lesions
  - Tracheitis/rhinitis/tonsillitis
  - Often absent

- Histo:
  - Meningoencephalitis (non-suppurative) with ganglioneuritis.
  - Neuronal and glial cell necrosis

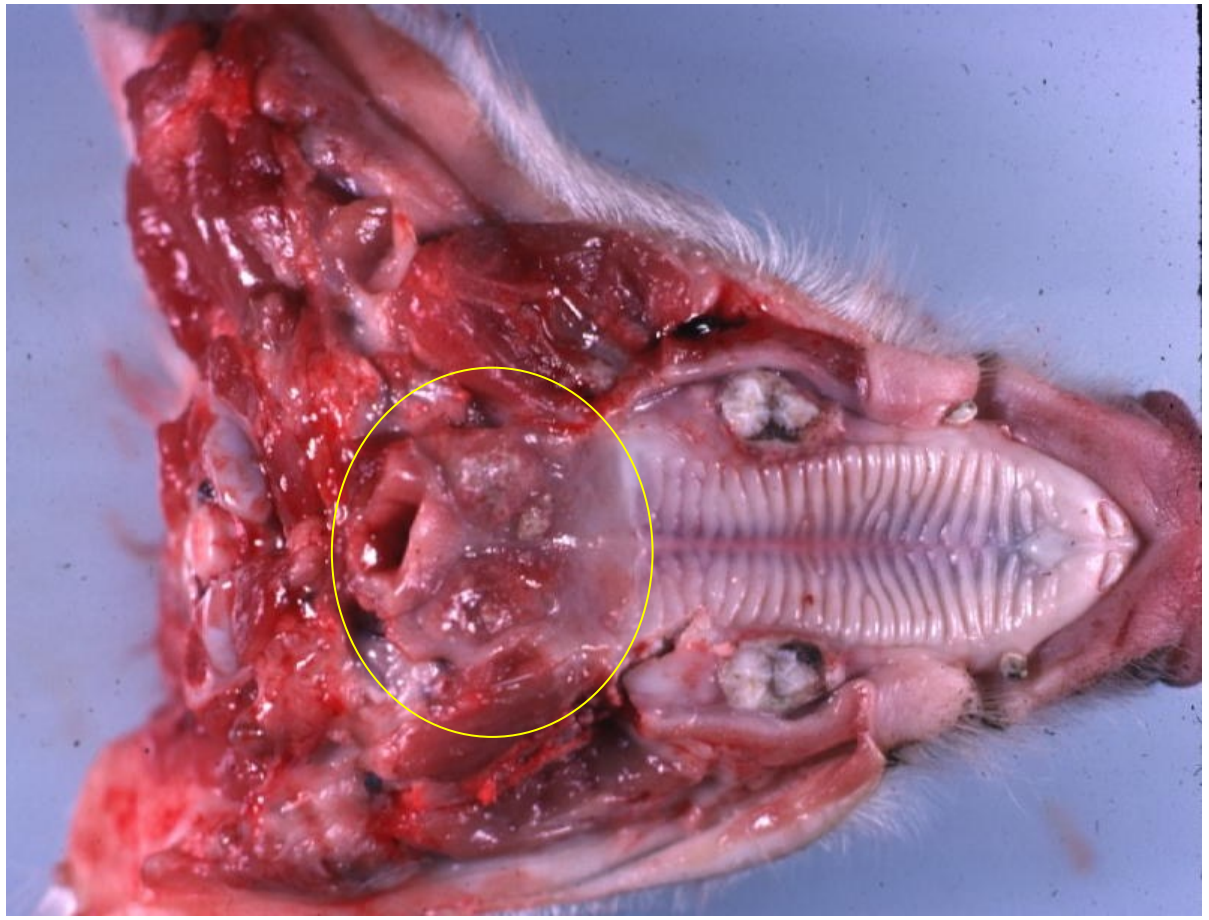

Necrotizing tonsilitis

SuHV-1 (Pseudorabies): clinical signs

- Non-pigs:
  - Transmission is typically direct or indirect contact with swine, usually via ingestion.
  - Intense pruritus at site of infection – “mad itch” – especially in **cattle**
  - Various nervous signs – especially in **dogs** and **cats**
    - Convulsions
  - Death in 1-2 days
    - Virtually always fatal in other mammals



SuHV-1 (Pseudorabies): diagnosis

- DDx:
  - Porcine polioencephalomyelitis (astrovirus)
  - Nipah virus
  - Classical swine fever (CSF) or African swine fever (ASF)
  - Streptococcal meningoencephalitis
  - Porcine parvovirus (SMEDI)
  - Rabies (all mammals)
  - Scrapie (sheep only)

SuHV-1 (Pseudorabies): diagnosis

- History, clinical signs (esp combination of pigs and other mammals) → highly suspicious
- Confirm with histopathology + IHC, or PCR on nervous tissue

- Control:
  - Good management – all-in, all-out
  - Vaccines are available
    - ↓ disease, do not prevent infection