

Lecture 23: Arteriviridae and Reoviridae

Russ Fraser, Fall 2023

Mark Schocken (USA)

Topics in this lecture

- Arteriviridae
  - Equine viral arteritis virus
  - Porcine respiratory and reproductive syndrome (PRRS)

- Reoviridae
  - Avian orthoreovirus
  - Rotaviruses
  - Orbiviruses

Arteriviridae

Size	45 - 60nm
Morphology	Enveloped
	• Icosahedral symmetry • Spherical
Genome	Linear, ssRNA, ~ 13 – 15 kb
Site of Replication	• Cytoplasm
Properties	• Host restricted • Preferentially infects macrophages • Can establish persistent, asymptomatic infections in their natural hosts



Equine arteritis virus

Equine arteritis virus: general

- Virus is present worldwide
- A disease of equids
- Infection is common, clinical disease is not
  - Asymptomatic infections predominate
  - Clinical signs depend on virulence of the infecting strain
  - Standardbreds and Warmbloods have a much higher prevalence
- Persistent infections can develop in stallions
  - No evidence for persistent infections in foals, geldings, or mares
  - Androgen dependent
  - Concentrates in the ampullae

Equine viral arteritis: transmission

- Primarily **respiratory** and **venereal** routes

- Sexually mature male horses that are infected with EVA may develop persistent infections
  - They are probably the most important source of virus
  - Do not necessarily display clinical signs of EVA
  - Can transmit via AI or natural cover

- Vertical transmission is possible
  - Abortion is the usual outcome of infection of naïve pregnant mares
  - Late-term infection may result in a live-born foal
    - The foal is weak and usually dies within days



Pinnacle Friesians/Cally Matherly

Equine viral arteritis: transmission

Most important method of international and farm-to-farm spread

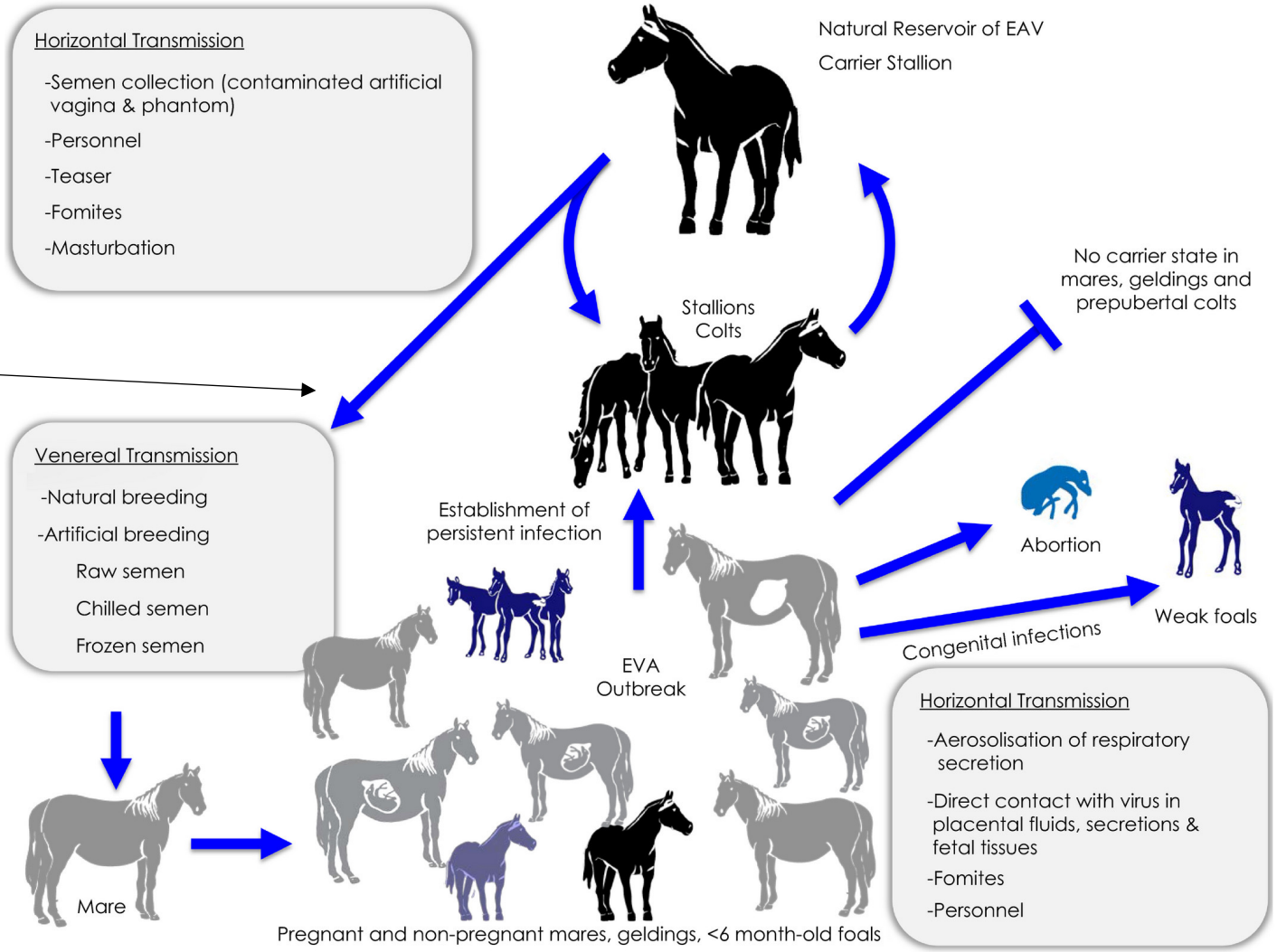

Most important method of spread on farm

Equine Veterinary Education, Volume: 30, Issue: 9, Pages: 497-512, First published: 10 November 2016, DOI: (10.1111/eve.12672)

Equine viral arteritis: pathogenesis

Inhalation

↓

Infection and replication in alveolar macrophages

↓

Local lymph nodes

↓

Viremia

↓

Infection of vasculature (panvasculitis)

Veins, lymphatics, and arteries

Equine viral arteritis: clinical signs

- Most infections are asymptomatic or mild
- Fever, anorexia, depression
- Ventral edema (limbs, scrotum, ventrum)
- Rhinitis, conjunctivitis
- Abortion in pregnant mares
- Rarely, in neonatal foals, severe pneumonia and death



Equine viral arteritis: clinical signs

- Most infections are asymptomatic or mild
- Fever, anorexia, depression
- Ventral edema (limbs, scrotum, ventrum)
- Rhinitis, conjunctivitis
- Abortion in pregnant mares
- Rarely, in neonatal foals, severe pneumonia and death

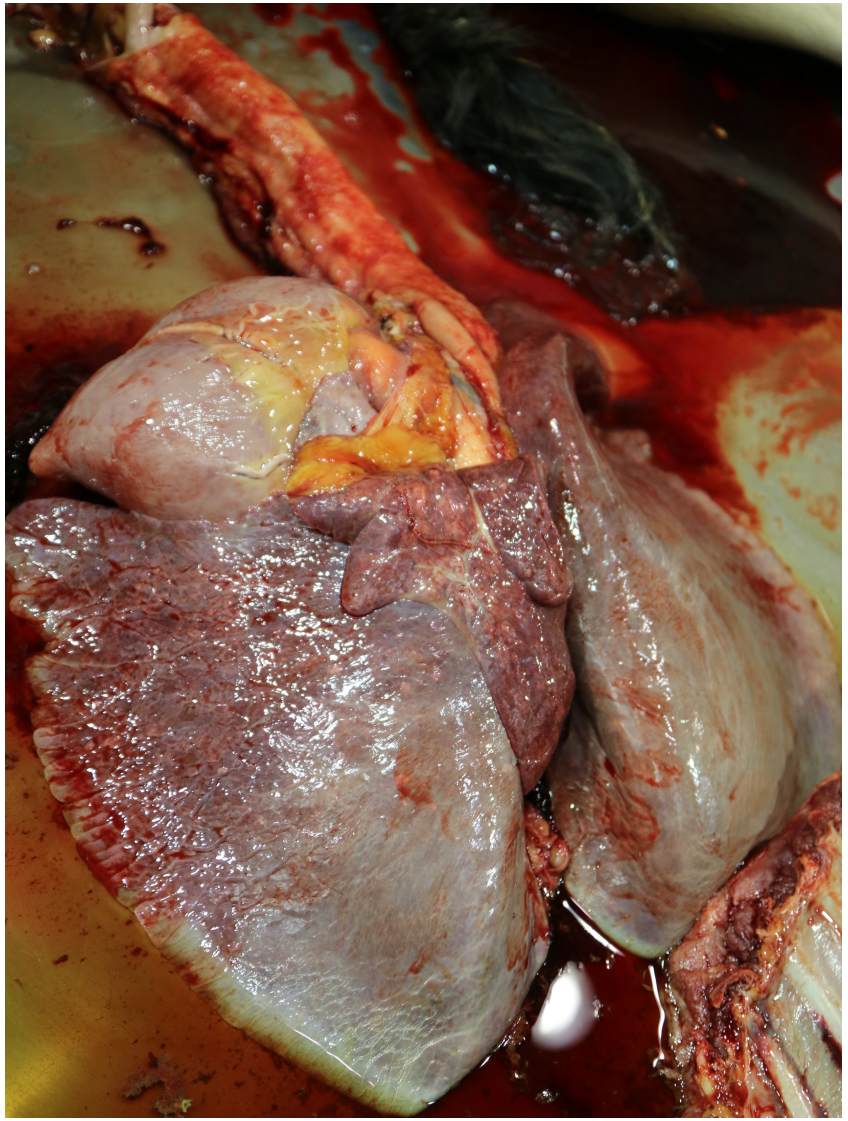

Equine viral arteritis: diagnosis

- DDx:
  - EHV-1, -4, EIA, equine influenza A virus
- Diagnosis
  - Serum antibody test
  - PCR
  - In breeding stallions:
    - Antibody to determine exposure followed by PCR on ejaculate

Equine abortion

	EHV-1	EAV
Mare	Asymptomatic	Symptomatic
Fetus	Fresh, liver lesions (pinpoint necrosis)	Autolyzed, no specific lesions (placenta may have vasculitis)

Equine arteritis virus: breeding

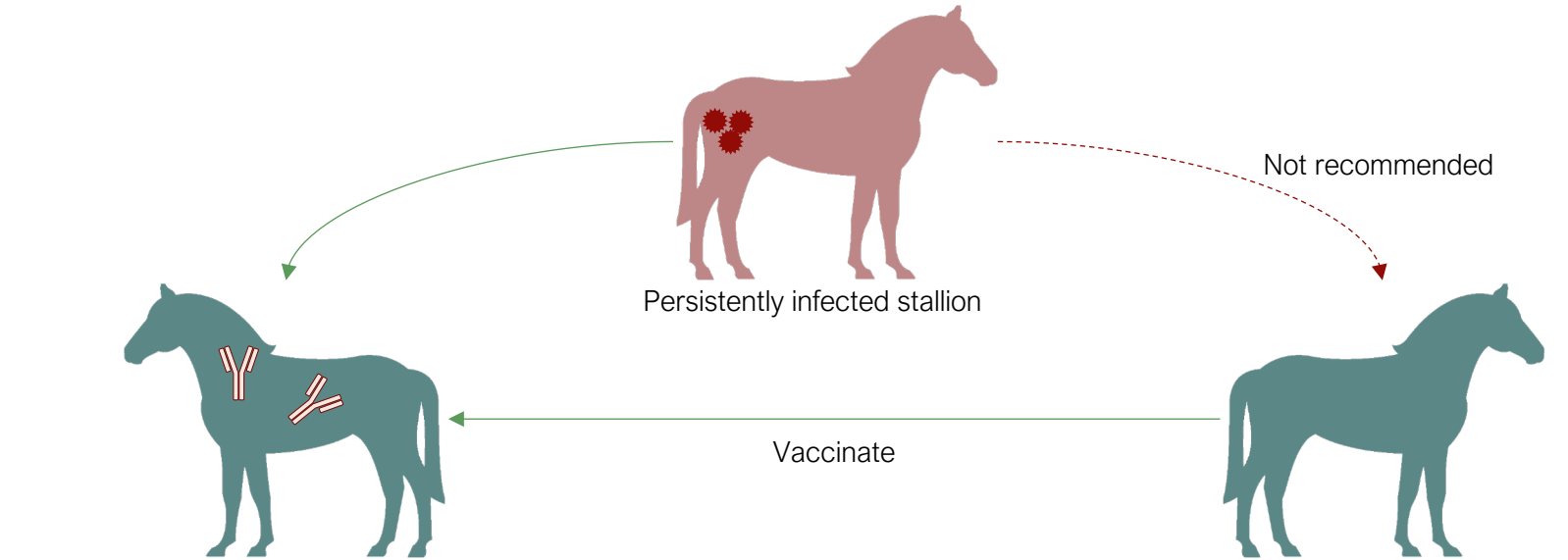

Equine viral arteritis: control

- Vaccination (MLV) is effective at reducing illness and reduces transmission
  - Antibody testing can NOT differentiate between infection and vaccination
- Recovered horses have long lasting immunity
- General biosecurity measures



Porcine respiratory and reproduction syndrome virus

PRRS (“purrs”)

PRRS: general

- "Mystery swine disease" in the '80s
- Genetically heterogeneous virus:
  - Type I – European
  - Type II – North American
- Worldwide distribution
- Reproductive failure and pneumonia

Assessment of the economic impact of porcine reproductive and respiratory syndrome virus on United States pork producers

Derald J. Holtkamp, DVM, MS; James B. Kliebenstein, PhD; Eric J. Neumann, DVM, MS, Member ANZCVS (Epidemiology); Jeffrey J. Zimmerman, DVM, PhD; Hans F. Rotto, DVM, MS; Tiffany K. Yoder, MS; Chong Wang, PhD; Paul E. Yeske, DVM, MS; Christine L. Mowrer; Charles A. Haley, DVM, PhD

Results: The total cost of productivity losses due to PRRSV in the US national breeding and growing-pig herd was estimated at US $664 million annually, an increase from the

PRRS: transmission

- "Spread by direct contact between infected and uninfected swine, including pugilism" ← ?????
- Virus is present in all secretions and excretions
  - Contaminated fomites likely contribute
- Aerosolized particles and venereal transmission are important
- Persistent, subclinical infections are an important source of virus
  - Virus can be recovered from oropharyngeal mucosa for ~ 6 months post-clinical signs



PRRS: pathogenesis

Inhalation

↓

Infection of local macrophages

↓

Lymph nodes

↓

Viremia

↓

Widespread infection of macrophages, pulmonary arteriolar endothelial cells

Apoptosis of macrophages

Impairment of host defenses

PRSS: clinical signs

- Depends on strain, herd immune status, etc
- Anorexia and lethargy in all age groups

- Neonates:
  - Dyspnea
  - ↓ growth rate
  - ↑ mortality
- Growers/finishers
  - Dyspnea, coughing
- Pregnant sows
  - Late-term abortion, stillbirths, mummies, weak piglets

PRRS: gross

- Interstitial pneumonia
  - Secondary bacterial pneumonia is common
- Generalized lymphadenopathy

Major differential diagnosis?

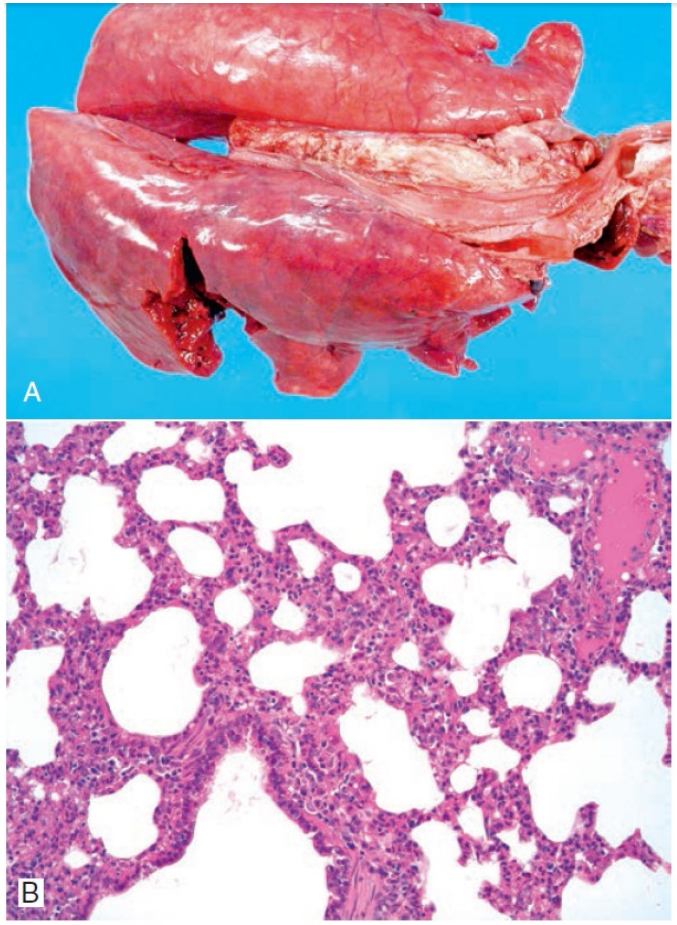

Figure 5-47 Porcine reproductive and respiratory syndrome. A. Grossly, the lungs show failure to collapse, diffuse firmness and rubbery texture, increased weight resulting from alveolar edema, and interlobular edema visible on the pleural surface. B. Diffuse thickening of alveolar septa by mononuclear cells. Lesions caused by circovirus or septicemia could appear similar.

PRRS: diagnosis and control

- DDx
  - Respiratory disease:
    - PCV-2, SIV, SHV-1, Nipah virus
  - Reproductive loss:
    - SHV-1, porcine parvovirus, PCV-2

- Diagnosis:
  - PCR and IHC on oral secretions, blood, or semen

- Control:
  - Immunity following infection is good, but might be strain specific
  - Biosecurity and management
  - Vaccination (MLV or inactivated)
    - ↑ amount of strain variation means occasional disease may still occur

Reoviridae



Reoviridae

Size	55 – 80 nm
Morphology	Naked (non-enveloped)
	• Icosahedral symmetry • Spherical
Genome	Segmented, dsRNA, ~ 18 - 27 kb
Site of Replication	• Cytoplasm
Properties	• Huge family of viruses • Antigenic shift and drift occurs

Reoviridae: important viruses

- Rotaviruses (in various species)
- Avian reovirus
- ★Bluetongue virus
- ★African horse sickness virus
- Epizootic hemorrhagic disease virus

Orbiviruses

Arboviruses

Rotavirus

- Rotaviruses cause diarrhea in neonatal and young mammals
- Animals in intensive production are more significantly affected
  - Pigs, calves
- Diarrhea is usually not fatal (in neonates)
  - Usually less severe than coronaviral diarrhea
- Pathogenesis is identical to coronaviral diarrhea
- Control is via management and vaccination of dams/sows



Avian reovirus

- Widespread in commercial flocks
- Many infections are asymptomatic
- Strain variation can occasionally lead to outbreaks:
  - Most common clinical manifestation is lameness (tenosynovitis)
  - Often young chicks (1 – 2 weeks)
  - Can be so severe that chick can not walk to feeders, water
  - Loss in production can be severe
    - Ontario outbreaks in 2017 → whole flocks depopulated
- Transmission is direct (chick-to-chick)
- Vaccines are available and are effective

Bluetongue virus

- An arbovirus with at least 27 different serotypes
- Important disease of sheep production in many countries
  - Infects many domestic and wild ruminants
- In N.A. more of an issue in cattle
  - Present in much of the USA
  - Semi-regular incursions into the Okanagan valley of BC occur
    - Due to the vector being blown in
- Some serotypes are reportable
  - Serotypes that circulate regularly in the USA are immediately notifiable

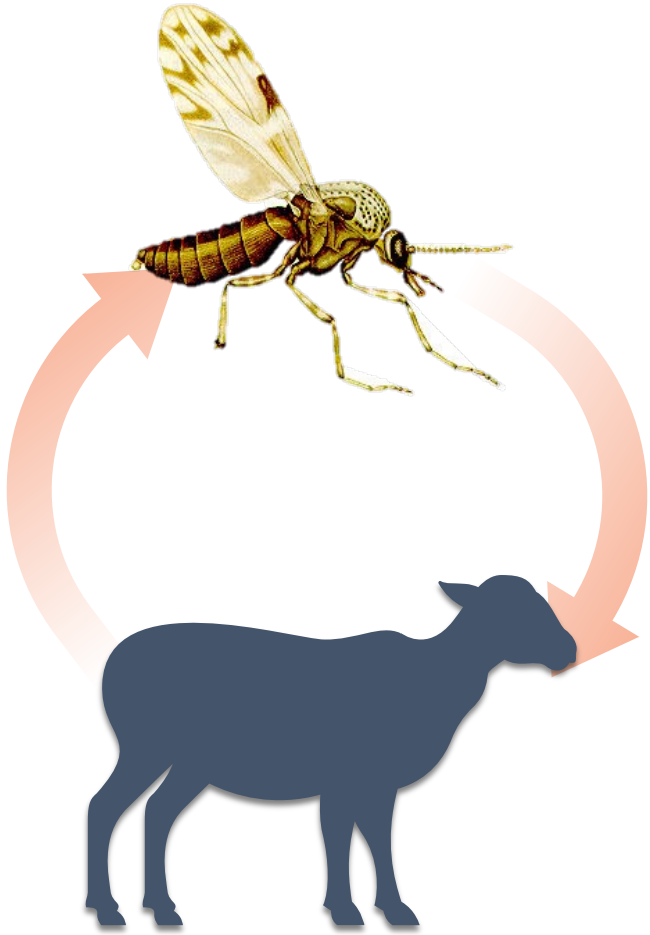

Bluetongue virus

- An arbovirus with at least 27 different serotypes

- Important disease of sheep production in many countries
  - Infects many domestic and wild ruminants

- In N.A. more of an issue in cattle
  - Present in much of the USA
  - Semi-regular incursions into the Okanagan valley of BC occur
    - Due to the vector being blown in

- Some serotypes are reportable
  - Serotypes that circulate regularly in the USA are immediately notifiable

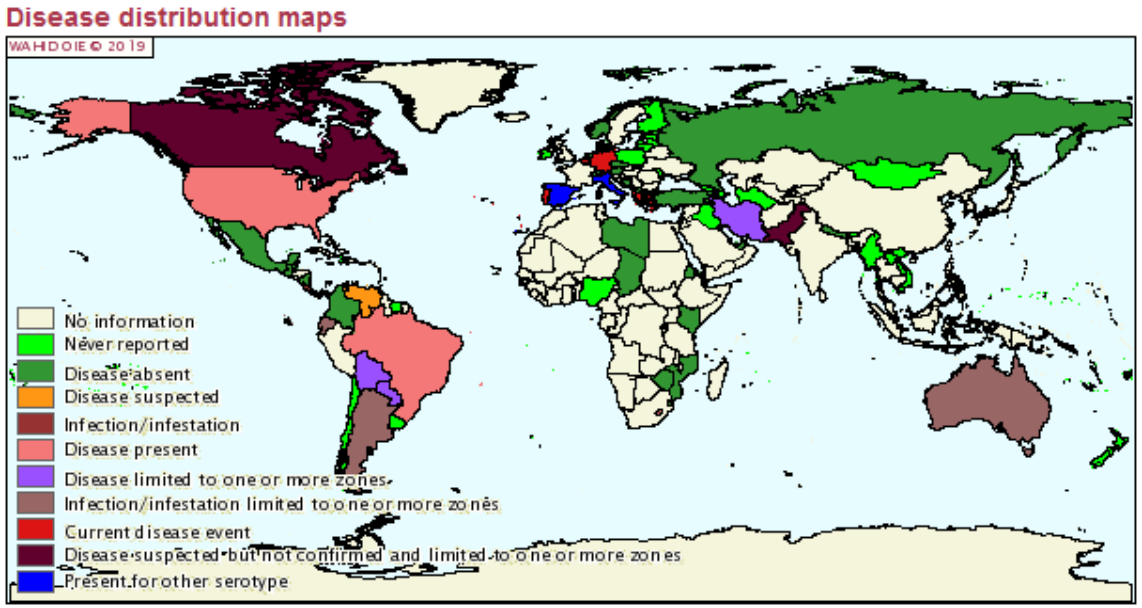

Bluetongue virus: pathogenesis

Injection of virus

↓

Replication in draining lymph node

↓

Viremia

↓

Vascular endothelium and all blood cell types (RBCs, platelets, leukocytes, etc)

↓

Vascular injury

↓

Thrombosis, infarction, ± DIC, vasculitis

Facilitates infection of vector

Bluetongue virus: clinical signs

- Disease is most severe in **sheep**
  - Oral ulcers and petechia
  - Protruding, swollen, and cyanotic tongue (rare)
  - Facial and aural edema
  - Reproductive failure
  - Ulcers and inflammation around the coronary band

- In **cattle**, asymptomatic infections are most common
  - Fever, oral ulcers, and ulcers on the teats are most common manifestations

- In **antelope and deer**, multifocal hemorrhage and death.

Bluetongue virus: lesions

- Protruding, cyanotic tongue.
- Eponymous lesion, but rare



Bluetongue virus: lesions

- Inflammation around the coronary band



Bluetongue virus: lesions

- Multifocal hemorrhage along the intimal surface of the pulmonary trunk

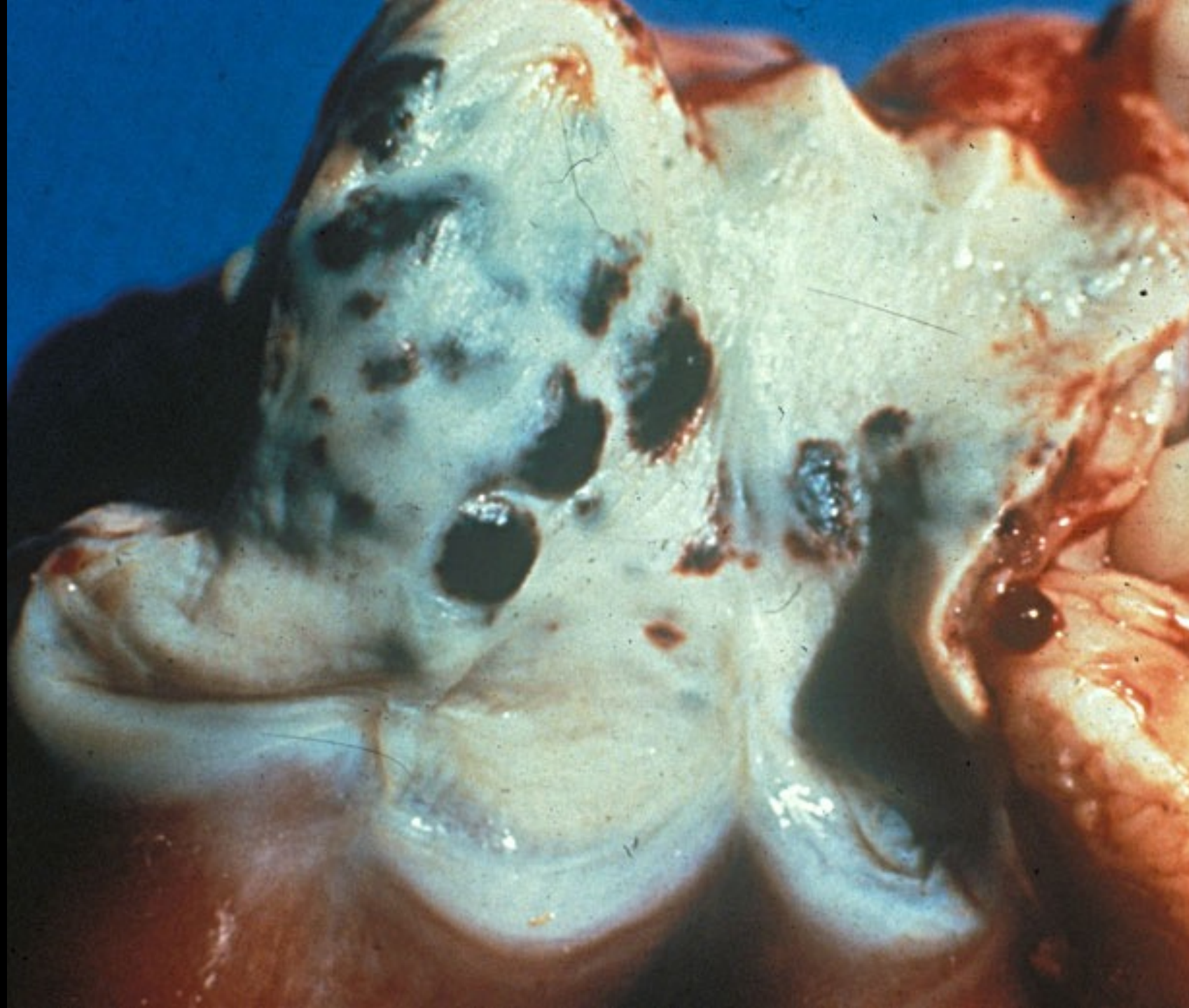

Bluetongue virus: lesions

- Hemorrhages along the adventitial surface of the pulmonary artery



20. **Bluetongue:** Sheep, pulmonary arterial trunk. Mural ecchymotic hemorrhage.
ce: OVI/ARC]

Bluetongue virus: lesions

- Pronounced submandibular subcutaneous edema



Bluetongue virus: lesions

- Thoracic effusion

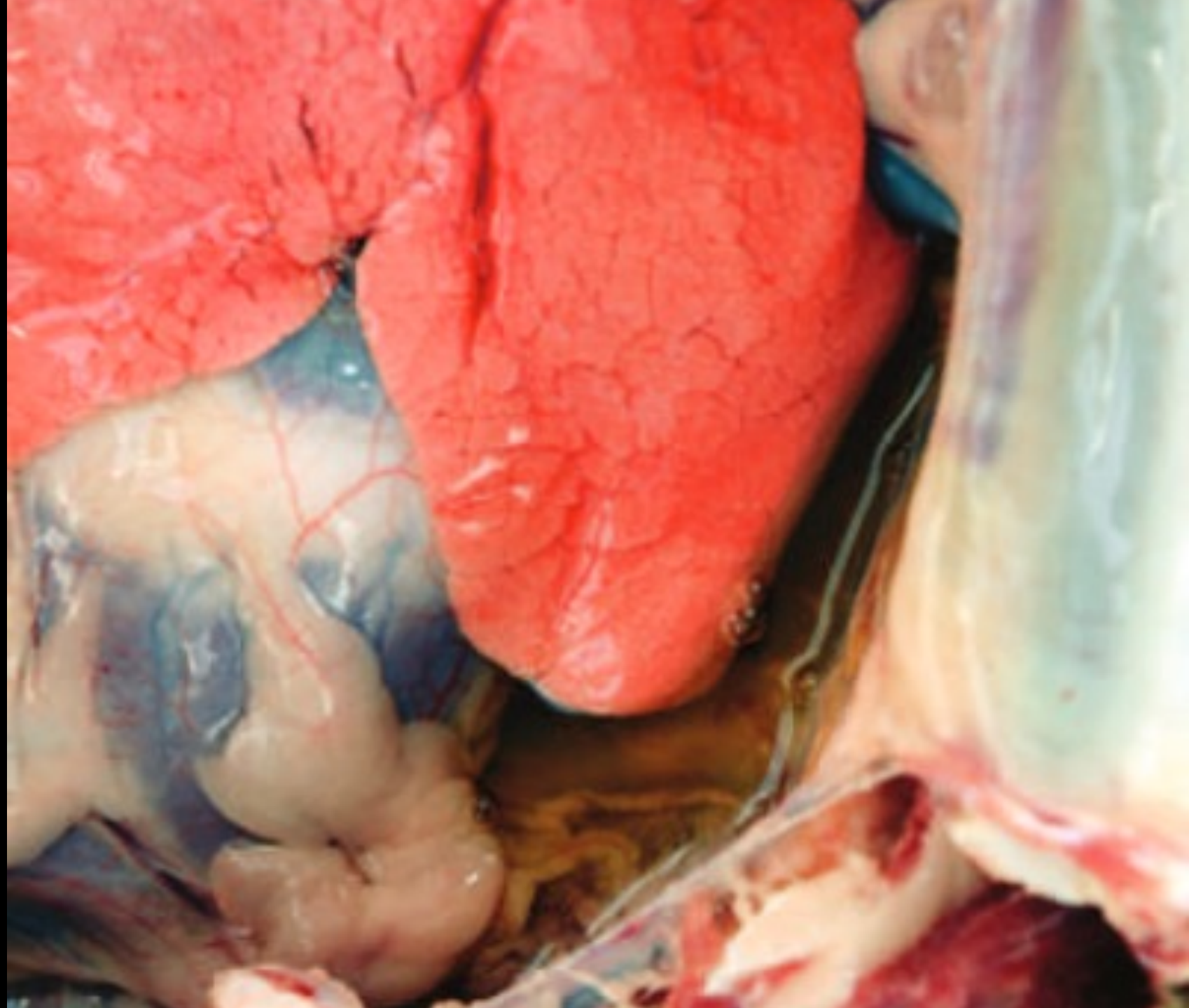

Bluetongue virus: lesions

- Pericardial effusion



Bluetongue: diagnosis

- DDx:
  - FMDV, PdPRV, MCF, BVDV, VSV, IBR
- Diagnosis:
  - If suspicious → CFIA
  - PCR
- Control:
  - Immunity is serotype specific
  - Vaccines are available
  - If reportable form → eradication, quarantine, etc.



African horse sickness virus

African horse sickness virus

- Highly fatal disease of horses (~95 % with some serotypes)
- Very similar to Bluetongue virus in many ways
- At least 9 serotypes
- Arbovirus (Culicoides)
- Pathogenesis is very similar
- Reportable

AHSV: clinical signs

- Vary considerably depending on serotype

- Pulmonary form (“dunkop”)
  - Rapidly progressing, severe dyspnea and death

- Cardiac form (“dikkop”)
  - Fever
  - Periorbital edema, conjunctival hemorrhage
  - Edema of face, tongue, laryngeal region

- Mixed ‘forms’ are common

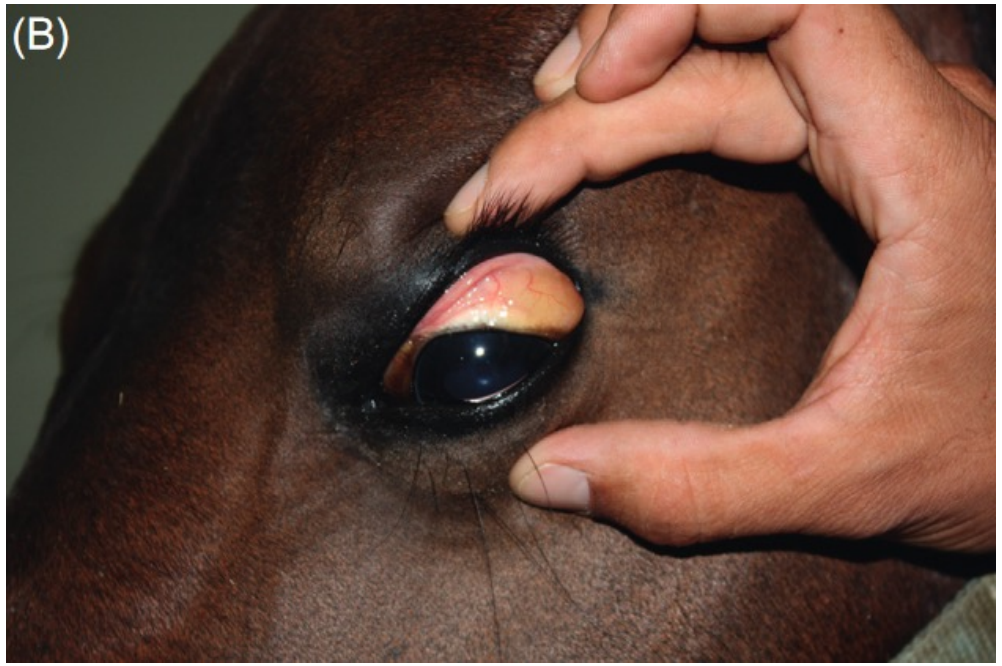

AHSV: gross lesions

- Pulmonary edema and hydrothorax
- Hydropericardium
- Generalized lymphadenopathy
- ± patchy hyperemia of GI tract
- ± focal hemorrhages on spleen, kidneys

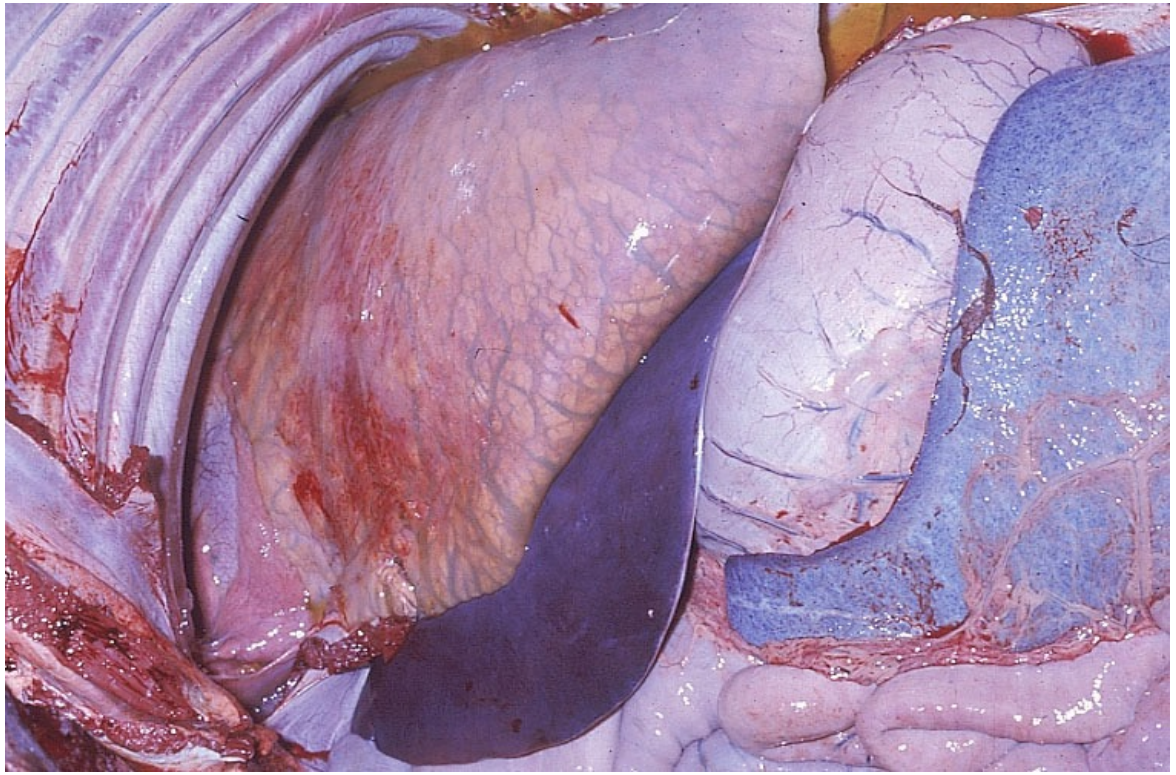

AHSV: gross lesions

- Pulmonary edema and hydrothorax
- Hydropericardium
- Generalized lymphadenopathy
- ± patchy hyperemia of GI tract
- ± focal hemorrhages on spleen, kidneys

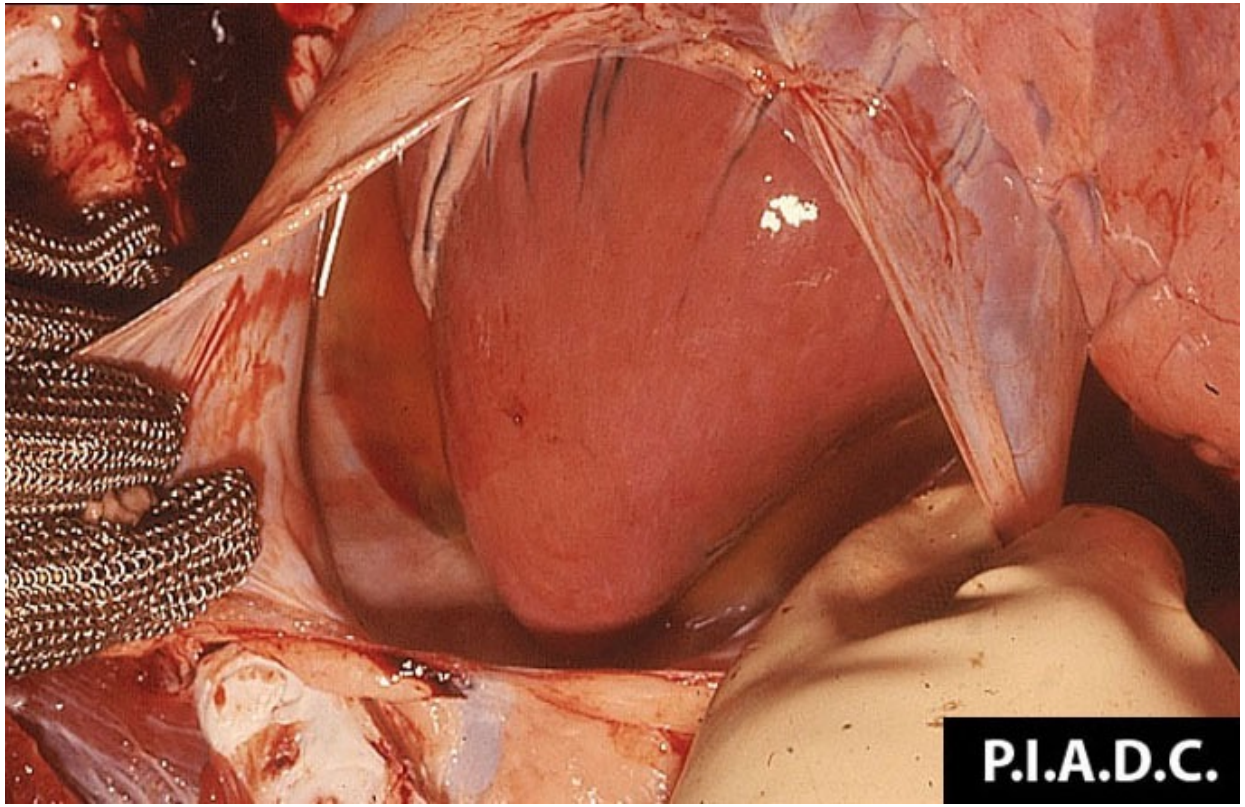

AHSV: gross lesions

- Pulmonary edema and hydrothorax
- Hydropericardium
- Generalized lymphadenopathy
- ± patchy hyperemia of GI tract
- ± focal hemorrhages on spleen, kidneys



AHSV: diagnosis and control

- DDx:
  - EVA, EIA, Hendra virus
- Diagnosis:
  - Virus isolation
  - PCR
- Control:
  - Eradicate, quarantine, etc.
  - MLV vaccines are available in endemic areas (Africa)