

Lecture 22 - Coronaviridae

Russ Fraser, Fall 2023

Coronaviridae

Size	80 - 220 nm
Morphology	Enveloped
	• Icosahedral symmetry • Spherical to pleomorphic
Genome	Linear, ssRNA, ~ 25 - 32 kb
Site of Replication	• Cytoplasm
Properties	• Infectious RNA • Spike (S) protein on surface determines tropism • Generally cause **respiratory** or **gastrointestinal** disease • Recombine frequently • Tend to infect a variety of species (e.g. SARS-CoV, SARS-CoV2, MERS, etc)



Infectious bronchitis

IB

Infectious bronchitis: general

- Economically important disease of chickens
  - Layers and broilers
- Characterized by respiratory disease and egg defects
- Transmission
  - Aerosol
  - Feco-oral
  - Can survive days on fomites, longer in colder temps



Infectious bronchitis: pathogenesis

Infection

↓

Replication in respiratory epithelium

↓

Viremia

↓

Infection of variety of organs

Kidney, oviduct and ovaries, intestine

Infectious bronchitis: clinical signs

- Variable and dependent on strain, age, genetic background, immune status, dietary Ca2+ levels, etc.
- Outbreaks are rapid (whole flock in 1-2 days)
- Chicks 1 – 4 weeks:
  - Severe respiratory disease with virulent strains
  - Gasping/respiratory distress
  - Coughing, sneezing, nasal discharge
  - Mortality ~ 25 – 30%
  - May result in ↓ egg quality later in life d/t oviduct hypoplasia
  - Secondary bacterial infections → ↑ mortality
- Egg-laying chickens
  - ↓ or cessation of egg-laying
  - When egg-laying resumes, eggs may have abnormalities including thin or poorly calcified shells, distorted shells. Albumen may be watery.



Infectious bronchitis: gross

- Mucosal thickening of U/LRT
- Exudate in the nasal passages, trachea, bronchi, air sacs
- Occasionally egg peritonitis
- Nephritis (some strains)

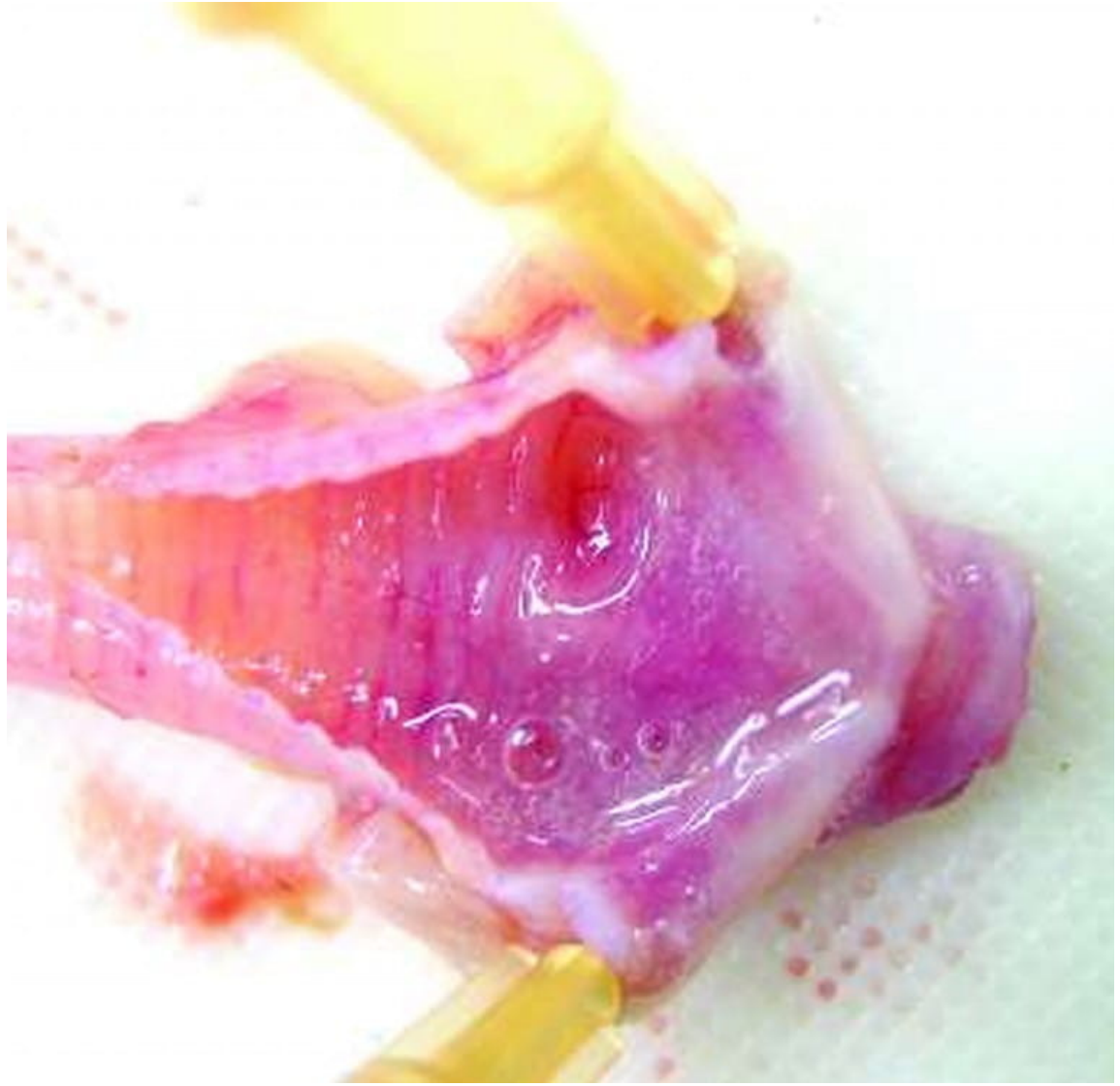

Infectious bronchitis: diagnosis and control

- DDx:
  - NDV, AIV, ILT
- Diagnosis:
  - Tracheal swabs or trachea for PCR or virus isolation
- Control:
  - Vaccination (MLV) is wide-spread.
  - Backyard flocks → resurgence?



Porcine enteric coronaviruses

Transmissible gastroenteritis and porcine epidemic diarrhea viruses

Porcine coronaviruses: general

- Economically very important diseases
  - Transmissible gastroenteritis (TGE)
  - Porcine epidemic diarrhea (PED)
    - Entered NA through the USA in 2014.

- Cause of significant morbidity and mortality, particularly in very young (< 1 week old) piglets.

- Present worldwide

- Often see peaks in the cold weather (virus survives better at ↓ temp)

TGEV and PEDV: transmission

- Spread is rapid
- Highly contagious
- Introduced to farms by infected pig or contaminated fomites (trucks, clothing, instruments, etc)



TGEV and PEDV: pathogenesis

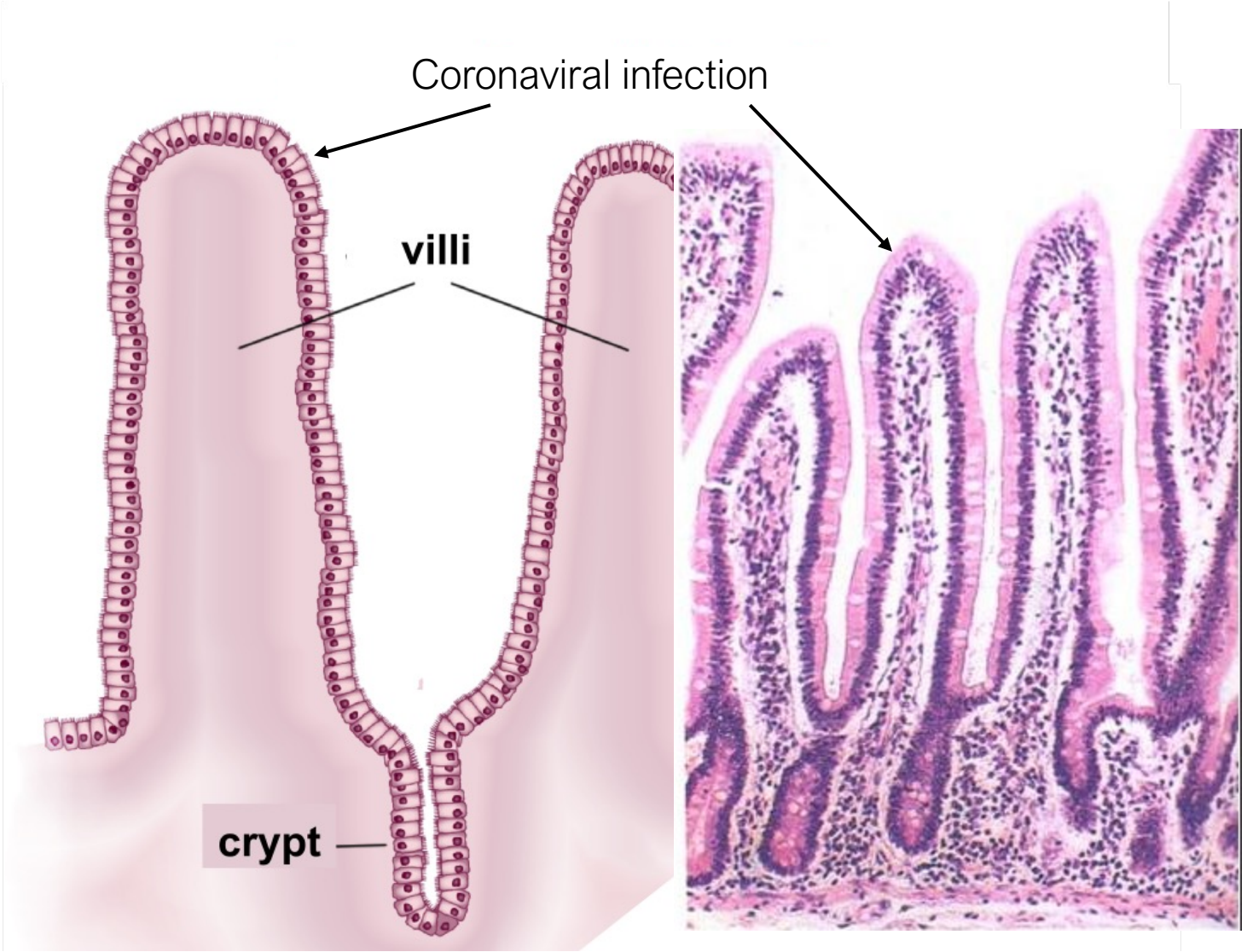

https://upload.wikimedia.org/wikipedia/commons/thumb/0/0e/Villi_&_microvilli_of_small_intestine.svg/1024px-Villi_&_microvilli_of_small_intestine.svg.png

TGEV and PEDV: pathogenesis

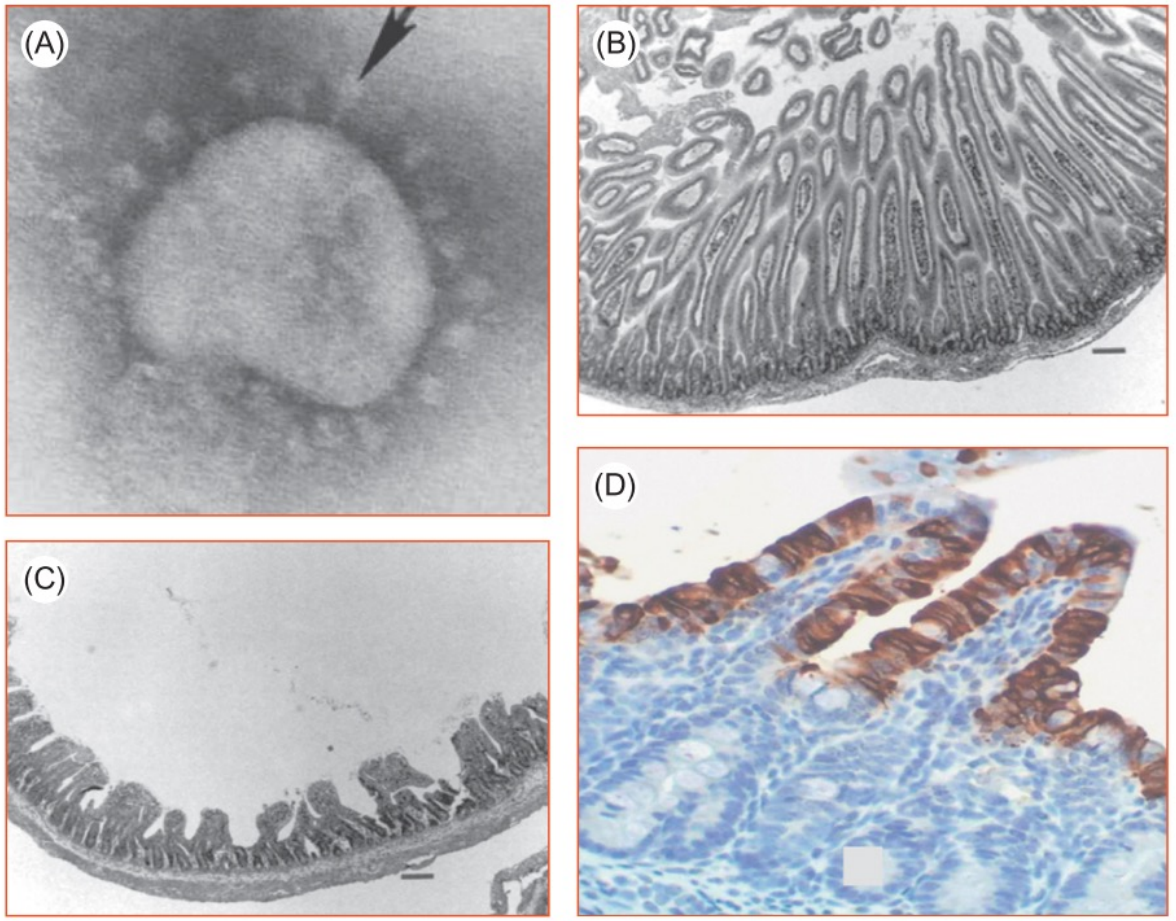

FIGURE 24.8 Pathogenesis of transmissible gastroenteritis. (A) Electron micrograph of causative virus, with prominent envelop spikes (arrow). Histologic appearance of small intestine of (B) normal piglet and (C) piglet with transmissible gastroenteritis. (D) Immunohistochemical staining showing selective viral infection of enterocytes lining the intestinal villi. *Courtesy of L. Saif, The Ohio State University.*

TGEV and PEDV: pathogenesis

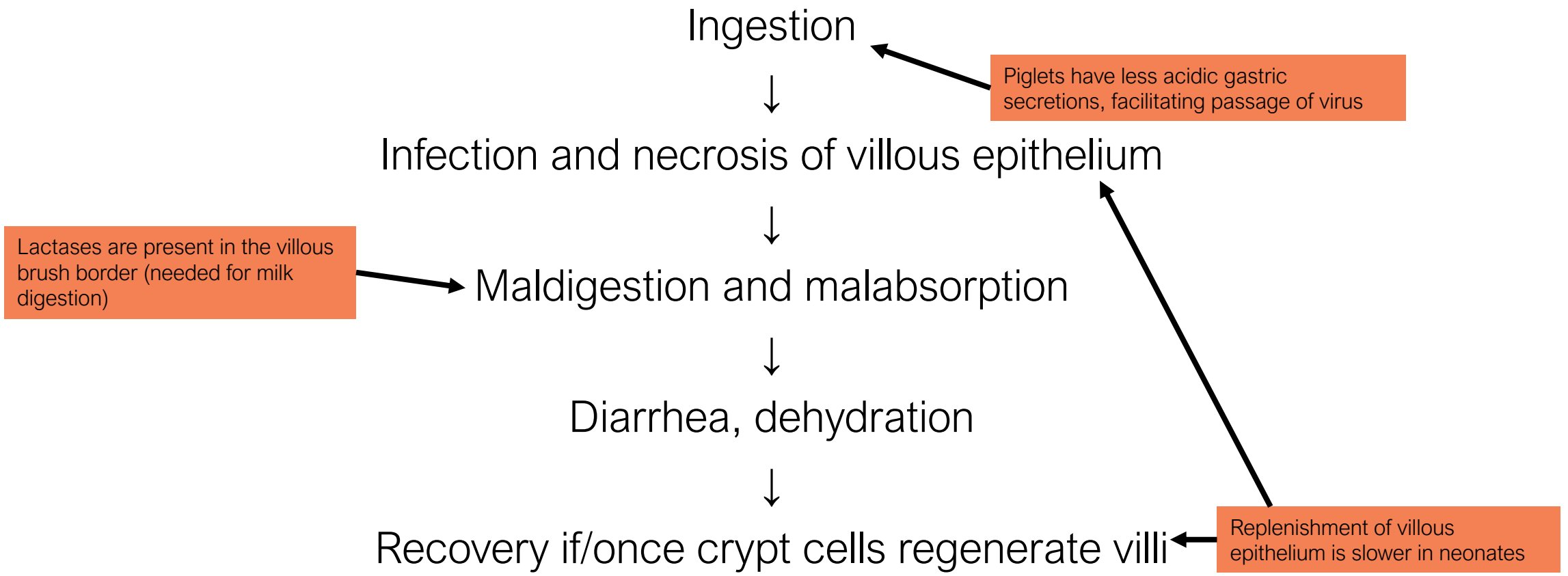

TGEV: clinical signs

- Epizootic TGE:
  - Virus is introduced to susceptible herd & clinical signs are severe
  - No herd immunity present
  - See next slide

- Enzootic TGE:
  - Sows are immune & TGEV persists on farm.
  - Disease is seen:
    - With frequent introductions of susceptible pigs
    - With continuous farrowing program
    - Clinical signs (mild & transient diarrhea) are noticeable at weaning in piglets 4-6 weeks old.

TGEV and PEDV: clinical signs (epizootic)

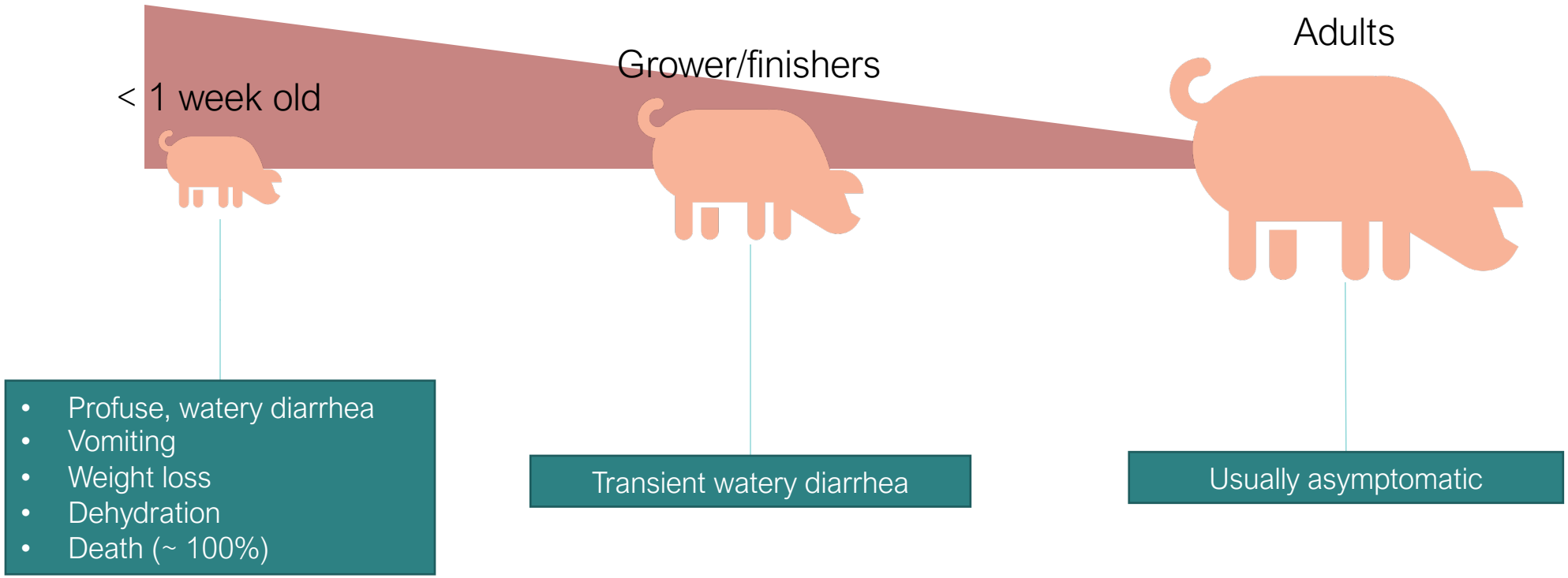

TGEV and PEDV: gross lesions



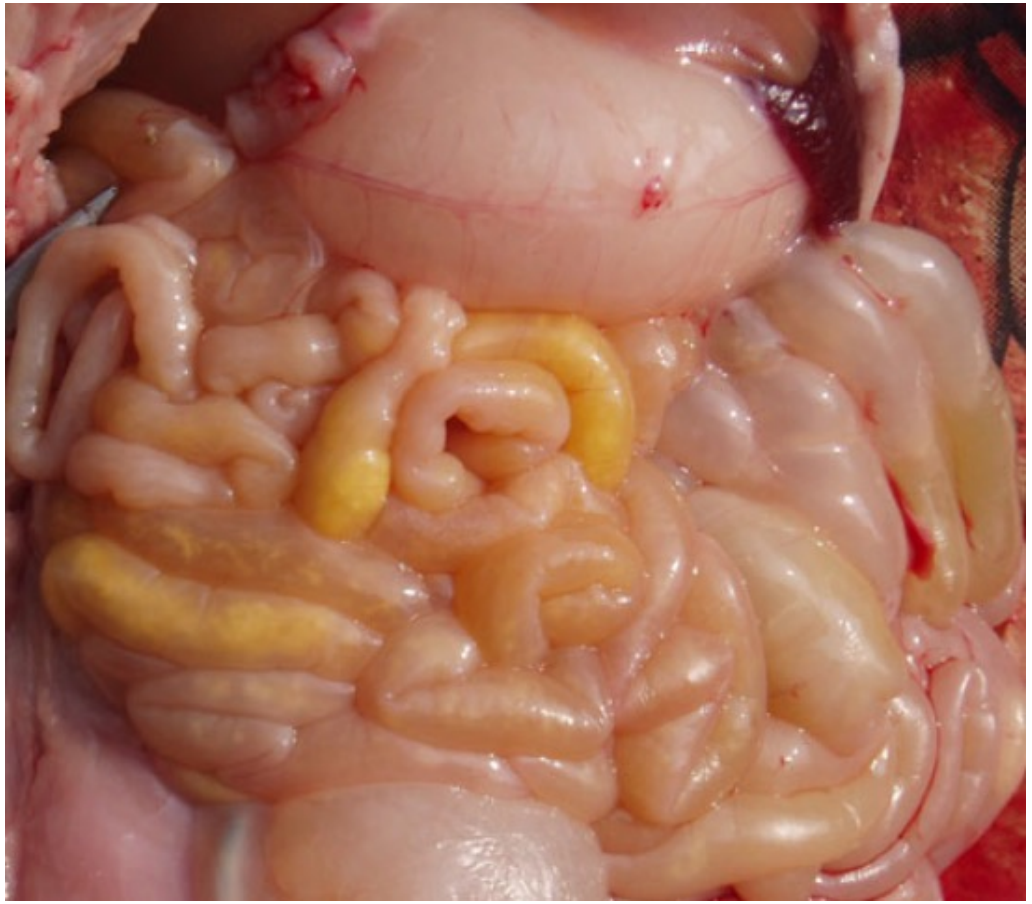

TGEV and PEDV: gross



TGEV and PEDV: diagnosis and control

- Immunity: recovered animals are immune

- DDx:
  - TGEV, PEDV, rotavirus

- Confirm by:
    - ELISA on feces (for antigen)
    - PCR
    - Virus isolation

- Control:
  - Good biosecurity is critical. All-in, all-out.
  - Good management practices to avoid introduction of virus on farm.
  - Vaccination of sows before farrowing, to provide colostral antibody & lactogenic immunity in piglets:
    - Use attenuated vaccines 3 weeks before farrowing, or
  - Farrow in disinfected premises.



Bovine coronavirus

Calf diarrhea, respiratory disease, and winter dysentery

Bovine coronavirus

- Common and present worldwide
- Manifests as three distinct syndromes:
  - Calf diarrhea
  - Respiratory disease (part of shipping fever)
  - Winter dysentery

- “Pneumoenteric” virus: infects both intestine and lung
- Transmission is by:
  - Respiratory droplets
  - Feco-oral
  - Direct contact

Bovine coronavirus: calf diarrhea

- Very similar to TGE:
  - Young (< 3 weeks old) calves
  - Co-infections are common
  - Diarrhea is severe and can be fatal



Bovine coronavirus: respiratory disease

- Causes respiratory disease in calves as well as a component of shipping fever or "BRDC"
- Somewhat controversial
  - Association vs causation?
  - Most seem fairly convinced that it plays a role – minor disease caused on its own, but when combined with secondary infections becomes more significant.

- Clinical signs:
  - Coughing, dyspnea
  - Rhinitis
  - Pneumonia
  - Fever
  - Anorexia

- Secondary infections are common (pure BCoV infection is rare)
- Gross lesions are reflective of shipping fever

Bovine coronavirus: winter dysentery

- Occurs primarily in winter months
  - Close proximity (housed indoors)
  - Virus survives better in the cold
  - Decreased UV light
- Highly contagious, low mortality
- Explosive diarrheal disease of adult (dairy) cattle
  - Often hemorrhagic or mucoid
- Clinical course is usually short: 2-3 days.
- Immunity lasts ~5 years.

Bovine coronavirus: diagnosis and control

- Differentials depend on the syndrome:
  - Neonatal calf diarrhea: rotavirus, bacterial or parasitic disease
  - Respiratory disease: viruses of shipping fever
  - Winter dysentery: possibly BVDV and MCF

- Control
  - Neonatal calf diarrhea: passive immunity – i.e. vaccinate cow
  - Understanding of respiratory mucosal immunity for protection against respiratory disease is poor
  - Vaccines have not been tested against winter dysentery



Equine enteric coronavirus

ECoV

- Recent association with severe enteric disease in **adults**
- Little known of epidemiology, transmission (likely feco-oral), or pathogenesis.
- Still poorly characterized: one study of 3 horses demonstrated:
  - Severe, necrotizing enteritis characterized by necrosis of villous epithelium
  - One horse had neurologic signs and brain lesions





Feline coronavirus

FECV, FIPV

FCoV: general

- Constantly undergoing drift, with variation widespread
- Feline coronavirus exists in two pathotypes:

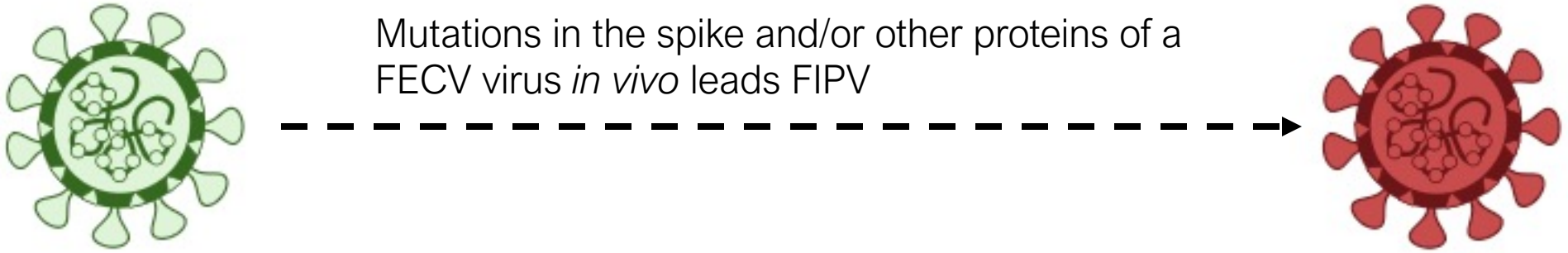

Feline enteric coronavirus (FECV)

Feline infectious peritonitis virus (FIPV)

FCoV: FECV



Feline enteric coronavirus (FECV)

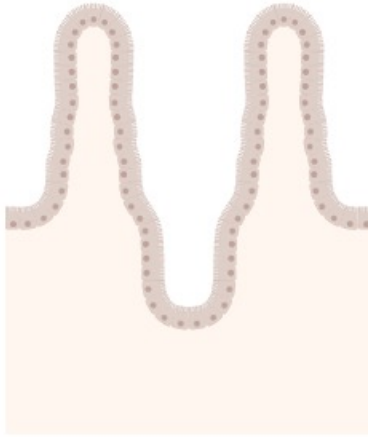

- Very widespread and common
- Kittens and some older cats
- Shelters, rescues, catteries are ↑ risk
- Feco-oral transmission
- Most infections are asymptomatic, occasionally causes diarrhea.
- Strong tropism for intestinal epithelial cells.
- FECV shedding is high for 2-10 months, followed by 3 possible outcomes:
  - Persistent but variable shedding for 9-24 months
  - Irregular shedding/non-shedding
  - Cessation of shedding

FCoV: FECV → FIPV



Feline enteric coronavirus
(FECV)

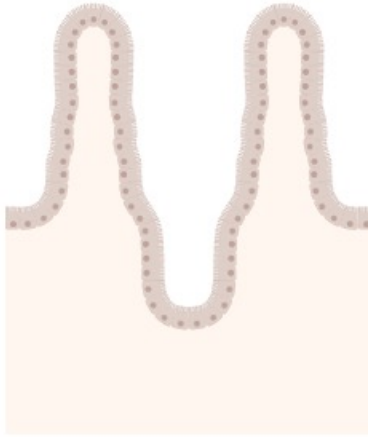

- Mutation in the spike (and/or other proteins) confers tropism for macrophages.

FCoV: FIPV



Feline infectious peritonitis virus (FIPV)



- **Mutation in the spike (and/or other proteins) confers tropism for macrophages.**
- FIPV is thus contained in tissues with limited access to the outside, **greatly limiting the transmissibility of FIPV.**

- What dictates when/where/why FeCV → FIV?
  - We don't really know.
  - Mutations in FECV are common, and can be detected even in cats that do not develop FIP.
  - Risk factors:
    - Younger age
    - ↑ numbers/density of cats shedding FeCV
    - Deficiences in immunity, incl. premature separation from queen
    - Purebreds

FIPV: pathogenesis

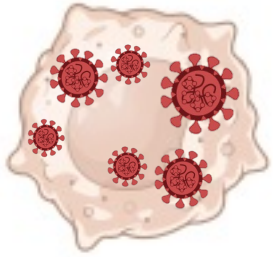

Some cats may recover at this stage (asymptomatic at this point)

Recruitment of additional møs

↓

"flamboyant cytokine storm", inflammation, and immune-mediated disease

↓

Complement, antibody bind to virus

↓

Immune complex deposition on vascular walls

↓

Vasculitis

↓

Edema, hemorrhage, thrombosis, clinical signs

FIPV: clinical signs

More common





Wet

effusive

Dry

non-effusive

FIPV: clinical signs and PE



Wet

- ADR and weight loss
- May have a history of vague repeated illness
- Diffuse peritonitis with abundant yellow modified transudate (75 %)



FIPV: clinical signs and PE



Wet

- ADR and weight loss
- May have a history of vague repeated illness
- Diffuse peritonitis with abundant yellow modified transudate (75 %)
- May also involve thorax (10-15 %) or both (< 10 %)
- CNS and ocular involvement ~ 10 % of cases

FIPV: clinical signs

- About 25 % of cats with FIP
- More difficult to identify
- CNS and ocular disease are more likely
  - CNS signs are sole sign in 22 % of cases
  - Ocular signs are sole issue in 14 % of cases
- Exact clinical signs depend somewhat on area of brain affected
- Uveitis is common, as is retinitis



Dry

non-effusive

FIPV: gross lesions

- Abundant yellow tinged fluid in the abdomen
- There is often abundant fibrin throughout

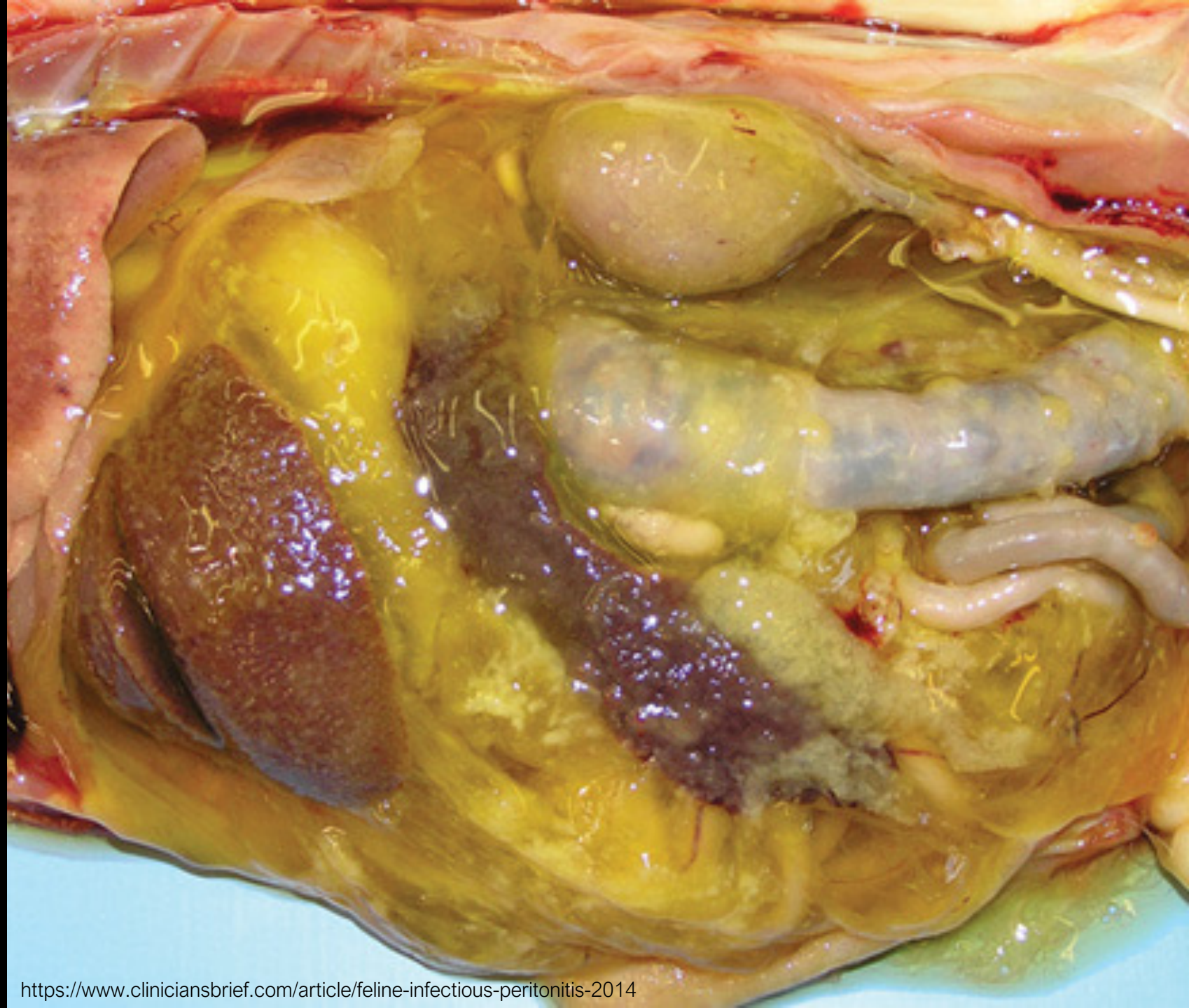

https://www.cliniciansbrief.com/article/feline-infectious-peritonitis-2014

FIPV: gross lesions

- Multifocal pyogranulomas on the surface of the kidney



FIPV: gross lesions

- Multifocal cortical pyogranulomas



FIPV: gross lesions

- Pyogranulomatous serositis of the mesentery

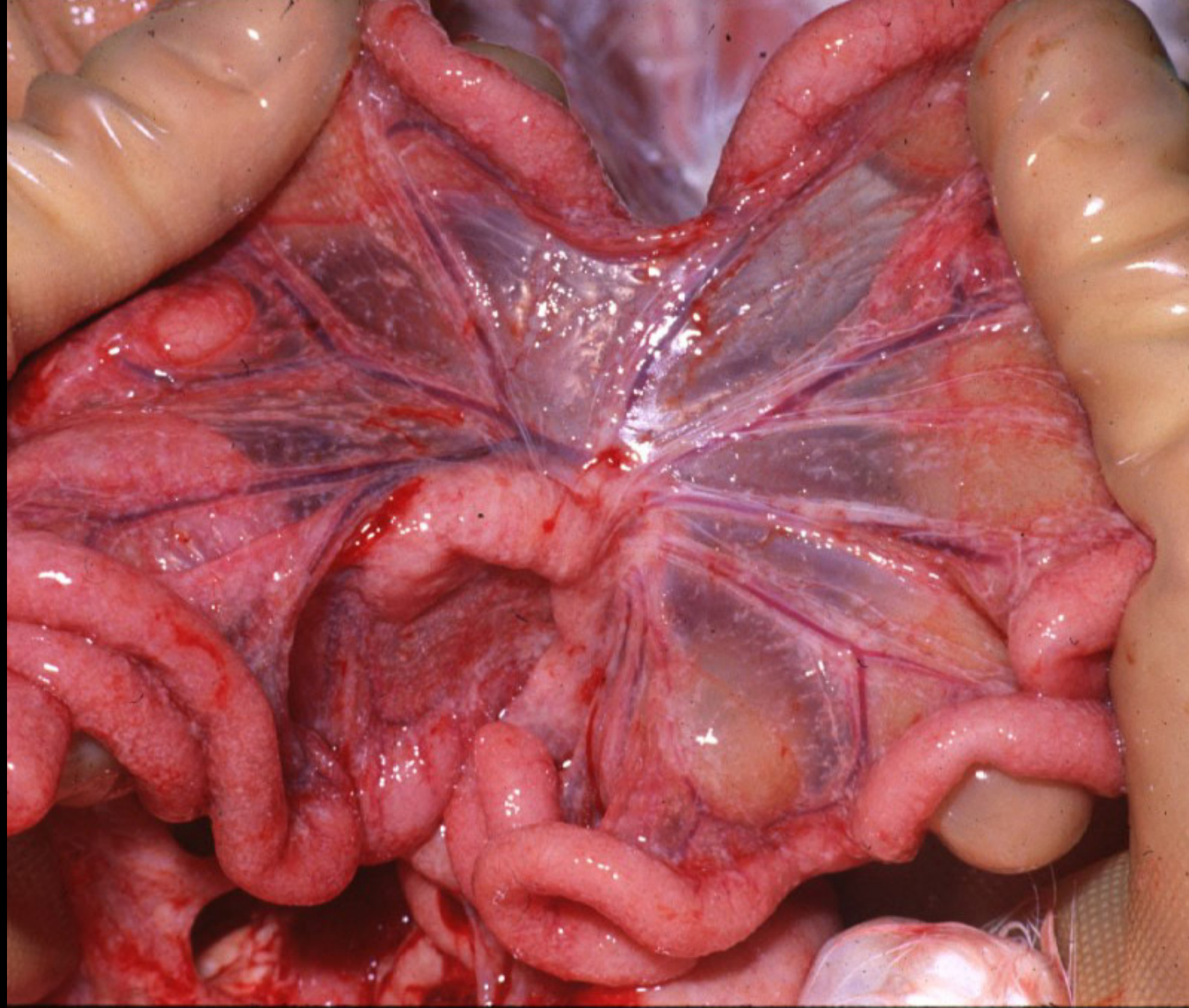

FIPV: diagnosis

- Combination of history (living environment), signalment, disease history, and PE findings.
- **Hyperglobulinemia is very common**.
- Anemia is common.
- Abdominal fluid is often a viscous modified transudate with high protein and moderate cell levels.
- PM: vasculitis and IHC for the virus in non-GI tissue.
- Serological and antigen tests are **not specific for FIPV.**
  - They detect both FECV and FIPV.
  - Very high antibody titres (along with clinical signs) are often indicative of FIPV.
  - Molecular tests are not particularly useful (detection of virus in ascites is diagnostic)

FIPV: treatment

SCIENCE

COVID Drugs Are a Miracle Cure for Cats

Leftover medications are going to save the animals from a deadly feline coronavirus.

By Sarah Zhang



Christina Assi / AFP / Getty

FIP: treatment

Journal of Feline Medicine and Surgery
Volume 21, Issue 4, April 2019, Pages 271-281
© The Author(s) 2019, Article Reuse Guidelines
https://doi.org/10.1177/1098612X19825701

SAGE journals

Original Article

Efficacy and safety of the nucleoside analog GS-441524 for treatment of cats with naturally occurring feline infectious peritonitis

Niels C Pedersen [1], Michel Perron [2], Michael Bannasch [1], Elizabeth Montgomery [1], Eisuke Murakami [2], Molly Liepnieks [3], and Hongwei Liu [3]

25/31 cats were in remission at the time of publication

FIP: treatment

Received: 9 November 2022 | Accepted: 13 July 2023

DOI: 10.1111/jvim.16832

CASE REPORT

Journal of Veterinary Internal Medicine
Open Access
ACVIM
American College of Veterinary Internal Medicine

Molnupiravir treatment of 18 cats with feline infectious peritonitis: A case series

Okihiro Sase

14/18 cats were in remission at the time of publication

FIPV: treatment

- None of these drugs are currently licensed for use.
- There are underground groups that help facilitate the procurement of black market drugs
  - e.g. Facebook “FIP Warriors”
  - Drugs come from various producers in China
  - Cost thousands of dollars

FIP: control

- ↓ density of animals in shelters/catteries
- Vaccines exist, but AAFP states “there is insufficient evidence that the vaccine induces clinically relevant protection, and use of the vaccine is not recommended”
- There are some complicated schemes for catteries to help reduce FeCV shedding (and thus FIP incidence)



SARS-CoV-2

COVID-19





No evidence of clinical signs, pathology, or seroconversion.

Pomorska-Mól et al. BMC Vet Res (2021) 17:322
https://doi.org/10.1186/s12917-021-03033-2















Study with 6 cattle.
2/6 had evidence of low levels of mild replication and seroconversion.

Ulrich, L., Wernike, K., Hoffmann, D., Mettenleiter, T. C., & Beer, M. (2020). Experimental Infection of Cattle with SARS-CoV-2. *Emerging Infectious Diseases*, *26*(12), 2979–2981. https://doi.org/10.3201/eid2612.203799

Can be infected, poor replication, do not secrete high amounts of virus, do seroconvert





Pigs inoculated with virus showed no clinical signs, viral replication, or seroconversion.

Meekins, D. A., Morozov, I., Trujillo, J. D., Gaudreault, N. N., Bold, D., Carossino, M., Artiaga, B. L., Indran, S. v., Kwon, T., Balaraman, V., Madden, D. W., Feldmann, H., Henningson, J., Ma, W., Balasuriya, U. B. R., & Richt, J. A. (2020). Susceptibility of swine cells and domestic pigs to SARS-CoV-2. *Emerging Microbes and Infections*, *9*(1), 2278–2288. https://doi.org/10.1080/22221751.2020.1831405





Chickens showed no clinical signs or evidence of seroconversion.

Schlottau, K., Rissmann, M., Graaf, A., Schön, J., Sehl, J., Wylezich, C., Höper, D., Mettenleiter, T. C., Balkema-Buschmann, A., Harder, T., Grund, C., Hoffmann, D., Breithaupt, A., & Beer, M. (2020). SARS-CoV-2 in fruit bats, ferrets, pigs, and chickens: an experimental transmission study. *The Lancet Microbe*, *1*(5), e218–e225. https://doi.org/10.1016/S2666-5247(20)30089-6









Highly susceptible, can shed virus, and infect other cats, but are usually asymptomatic

Bosco-Lauth, A. M., Hartwig, A. E., Porter, S. M., Gordy, P. W., Nehring, M., Byas, A. D., VandeWoude, S., Ragan, I. K., Maison, R. M., & Bowen, R. A. (2020). Experimental infection of domestic dogs and cats with SARS-CoV-2: Pathogenesis, transmission, and response to reexposure in cats. *Proceedings of the National Academy of Sciences of the United States of America*, *117*(42), 26382–26388. https://doi.org/10.1073/pnas.2013102117

Evidence of seroconversion but no shedding or clinical signs/symptoms

Pusterla N. Equine Coronaviruses. Vet Clin North Am Equine Pract. 2023 Apr;39(1):55-71. doi: 10.1016/j.cveq.2022.11.008. Epub 2022 Nov 21. PMID: 36737293.



USDA Statement on the Confirmation of COVID-19 in a Tiger in New York

Published: Apr 5, 2020

Print

Contact:
APHISpress@usda.gov

(Washington, D.C. April 5, 2020) – The United States Department of Agriculture's (USDA) National Veterinary Services Laboratories has confirmed SARS-CoV-2 (the virus that causes COVID-19 in humans) in one tiger at a zoo in New York. This is the first instance of a tiger being infected with COVID-19. Samples from this tiger were taken and tested after several lions and tigers at the zoo showed symptoms of respiratory illness.

Public health officials believe these large cats became sick after being exposed to a zoo employee who was actively shedding virus. The zoo has been closed to the public since mid-March, and the first tiger began showing signs of sickness on March 27. All of these large cats are expected to recover. There is no evidence that other animals in other areas of the zoo are showing symptoms.

This Photo by Unknown Author is licensed under CC BY-SA