

Lecture 15: Poxviridae

Russ Fraser, Fall 2023

Oil painting by E. E. Hillemacher, 1884

Poxviridae

Size	Large: 220 – 450 nm
Morphology	Enveloped and complex
	Brick and oval forms
Genome	linear, dsDNA, 130-375 kbp
Site of Replication	• Cytoplasm (!)
Properties	• Eosinophilic intracytoplasmic inclusions • Some are highly specific to keratinocytes → skin disease • Others infect a variety of epithelial cells → severe systemic D+ • Most are host specific (though some infect species widely, including humans) • Quite stable in the environment (envelope not required for infectivity), usually in scabs

Poxviridae

- In North America, 3 poxviruses are endemic and have significant economic significance:
  - Swinepox virus
  - Fowlpox virus & other avian poxviruses
  - Orf virus (contagious ecthyma)

- There are some circulating poxviruses that are of minor concern:
  - Bovine popular stomatitis virus
  - Pseudocowpox virus

- There are 3 foreign and reportable poxviruses:
  - Sheeppox virus
  - Goatpox virus
  - Lumpy skin disease virus

- Some poxviruses have significant human consequences:
  - Monkeypox virus
  - Smallpox (eradicated)



In honor of the world's last recorded smallpox case in Somalia in 1977, a Congolese artist carved a wooden statue of a patient looking up as he awaits a helicopter flying to his rescue.

Table: SUBFAMILY: ***CHORDOPOXVIRINAE***

Genus	Virus	Geographical distribution
Orthopoxvirus	Vaccinia	Worldwide
	Smallpox (Variola major)	Eradicated worldwide in 1980
	Cowpox	Europe, Asia
	Camelpox	Asia, Africa
	Uasin Gishu disease	Eastern Africa
	Monkeypox	**West & Central Africa (imported to USA in April 2003)**
	Raccoonpox	**North America**
	Skunkpox	North America
Parapoxvirus	**Pseudocowpox (Milker's nodule)**	**Worldwide**
	Bovine papular stomatitis	**Worldwide**
	Orf (Contagious ecthyma)	**Worldwide**
	Sealpox	Worldwide
	Ausdyk disease	Africa, Asia
	Parapox of red deer (1987)	New Zealand
Capripoxvirus	Sheeppox	Africa, Asia
	Goatpox	Africa, Asia
	Lumpy skin disease (Neethling)	Africa
Avipoxvirus	**Fowlpox**	**Worldwide**
	Canarypox, Pigeonpox, Turkeypox, Quailpox, Lovebirdpox etc	
Leporipoxvirus	**Myxoma, Rabbit (Shope) fibroma**	**Americas, Europe, Australia**
	Hare fibroma	Europe
	Squirrel fibroma	North America
Suipoxvirus	**Swinepox**	**Worldwide**
Molluscipoxvirus	Molluscum contagiosum	Worldwide
Yatapoxvirus	Yabapox and tanapox	West Africa

Refer also to Table 7.1, pg 153, in Fenner's Veterinary Virology, 4th edition.

Reportable

Poxviridae

- Transmission is generally:
  - Cutaneous – skin contact through abrasions
  - Respiratory route – aerosolized virus
  - Mechanical transmission – including lice.
- Lesions vary, and may be caused by:
  - Epithelial cell degeneration (from viral replication)
  - Vascular damage from replication in endothelium
  - Hyperplasia (genes mimicking growth factors)



Tametomo banishes the smallpox demon from the Island of Oshima. Colour woodcut by Yoshikazu, 1851/1853. Credit: Wellcome Collection. CC BY

Poxviridae

Papules are solid, circumscribed, elevations in the skin that are <1 cm in diameter

Pustules are accumulations in skin that are filled with inflammatory cells, usually neutrophils or eosinophils.

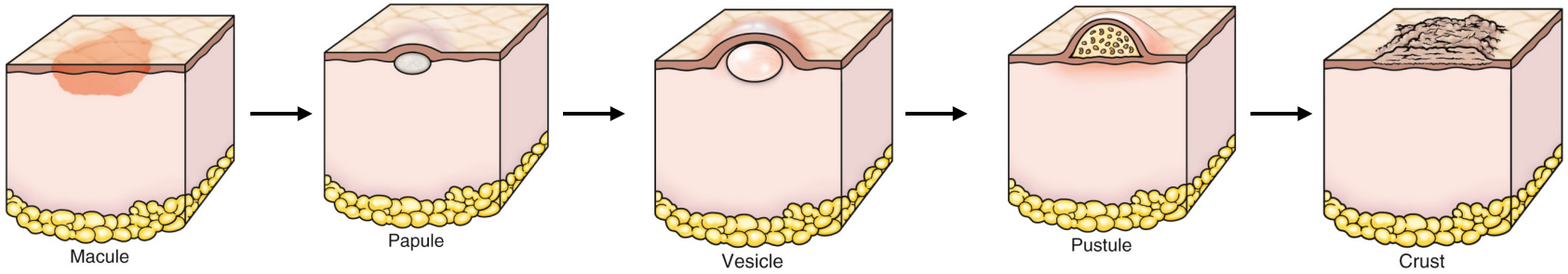

Macules are non-raised lesions of <1.0 cm diameter in which the color differs from that of the surrounding normal skin

Vesicle is a *fluid-filled blister* <1.0 cm in diameter (can be epidermal or dermal).

Crusts are composed of dried exudate composed of various components, including fluid, blood, pustular debris, scale, or microorganisms on the skin surface

Images from Pathologic Basis of Vet Disease

Poxviridae

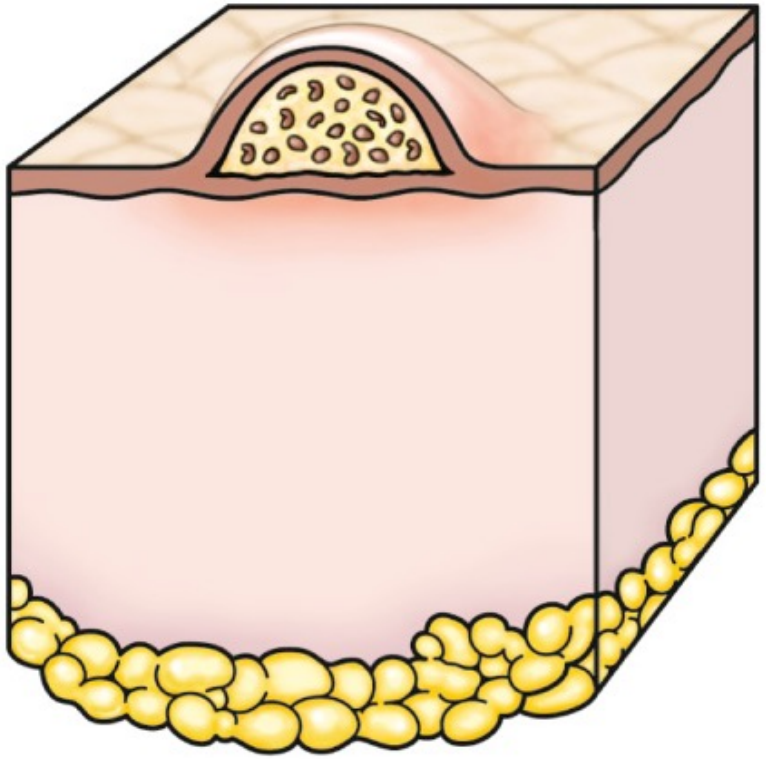

Pustule



Umbilicated pustules with a depressed center and a raised, often erythematous border are the so-called “pocks”

Images from Pathologic Basis of Vet Disease

Poxviridae

- Cell-mediated immunity is very important
  - Antibodies are not enough for protection.
  - Colostrum is not fully protective.



Sheep's head showing signs of smallpox. Coloured etching, 1840/1860?. Credit: Wellcome Collection. CC BY

Poxviridae: smallpox

- Genus Orthopoxvirus:
  - Has members of historic importance, i.e. smallpox (variola virus)
    - Smallpox was eradicated worldwide in 1980 – link to TED-Ed video on smallpox
  - The genus is highly homogenous, allowing cross-transmission & a high degree of antigenic similarity (recognized by Edward Jenner in 1796, & used as basis for vaccination against Smallpox with cowpox virus).
    - Smallpox is indistinguishable from monkeypox in humans.
  - Vaccinia virus and other poxviruses are now studied & used as a recombinant vector vaccine:
    - E.g. To vaccinate cats against rabies virus.



Gloucester smallpox epidemic, 1896: George Allen, a smallpox patient. Photograph by H.C.F., 1896. Credit: Wellcome Collection. CC BY



Gloucester smallpox epidemic, 1896: Ephraim Beard, a smallpox patient. Photograph by H.C.F., 1896. Credit: Wellcome Collection. CC BY

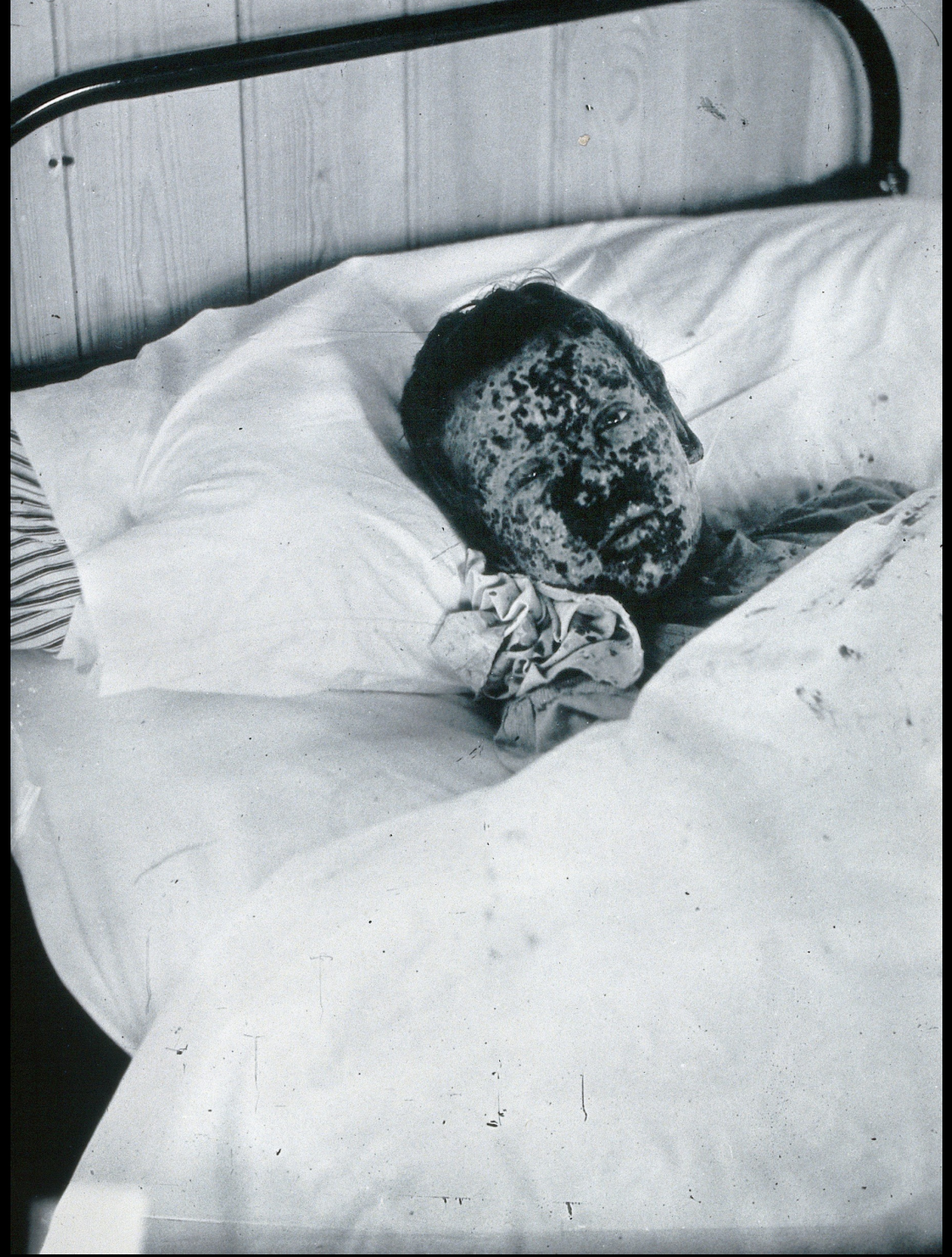

Gloucester smallpox epidemic, 1896: J.R. Evans, aged 10 years, a smallpox patient. Photograph by H.C.F., 1896. Credit: Wellcome Collection. CC BY



Gloucester smallpox epidemic, 1896: Kate Mills, a smallpox patient. Photograph by H.C.F., 1896. Credit: Wellcome Collection. CC BY



PLATE XXIV.

This case was exceptional because the trunk almost entirely escaped the invasion, behind as well as in front. The normal gradation in density on the limbs is well shown; but, as often happens to children, the density on the legs equalled, or almost equalled, that on the arms.

Child with Smallpox. Credit: Wellcome Collection. CC BY



Male smallpox patient with lesions on upper body, arms, face, and neck. Source: CDC's Barbara Rice.


mpox

Poxivirdae: mpox (formerly monkeypox)

Total count of confirmed cases of mpox by province or territory (Last data update September 29, 2023)

Hover over or tap regions to see cases, in Canada over time. Map data is available in .csv and .json formats.

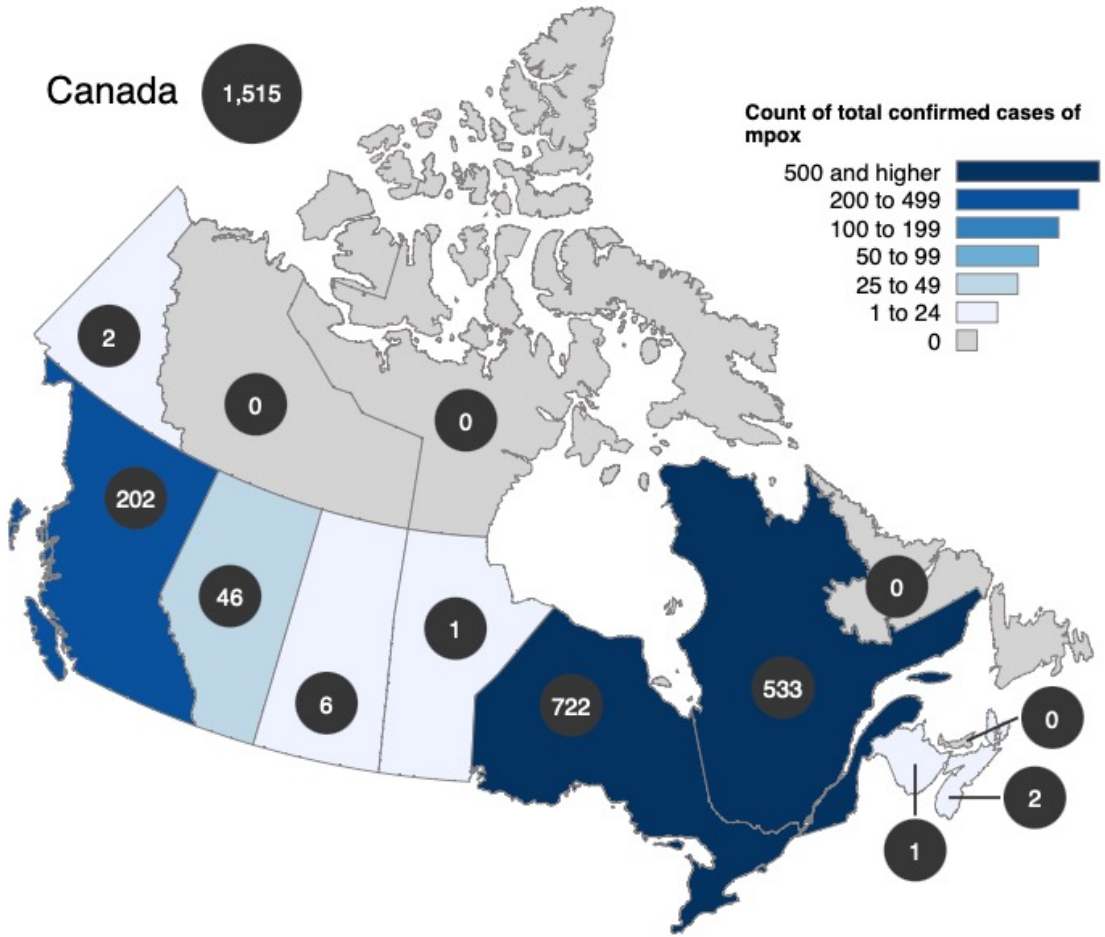

The total count of confirmed cases of mpox in **Canada** was **1,515** as of **September 29, 2023**.

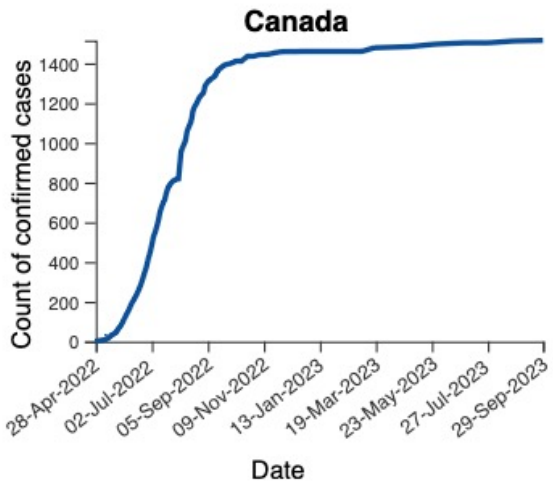

Download the data

Poxviridae: mpox

Figure 2. Total number **of confirmed mpox cases (n=1,443) in Canada by date as of September 29, 2023, 12 pm Eastern**

98.27% of confirmed mpox cases are among people who identify as men [1].

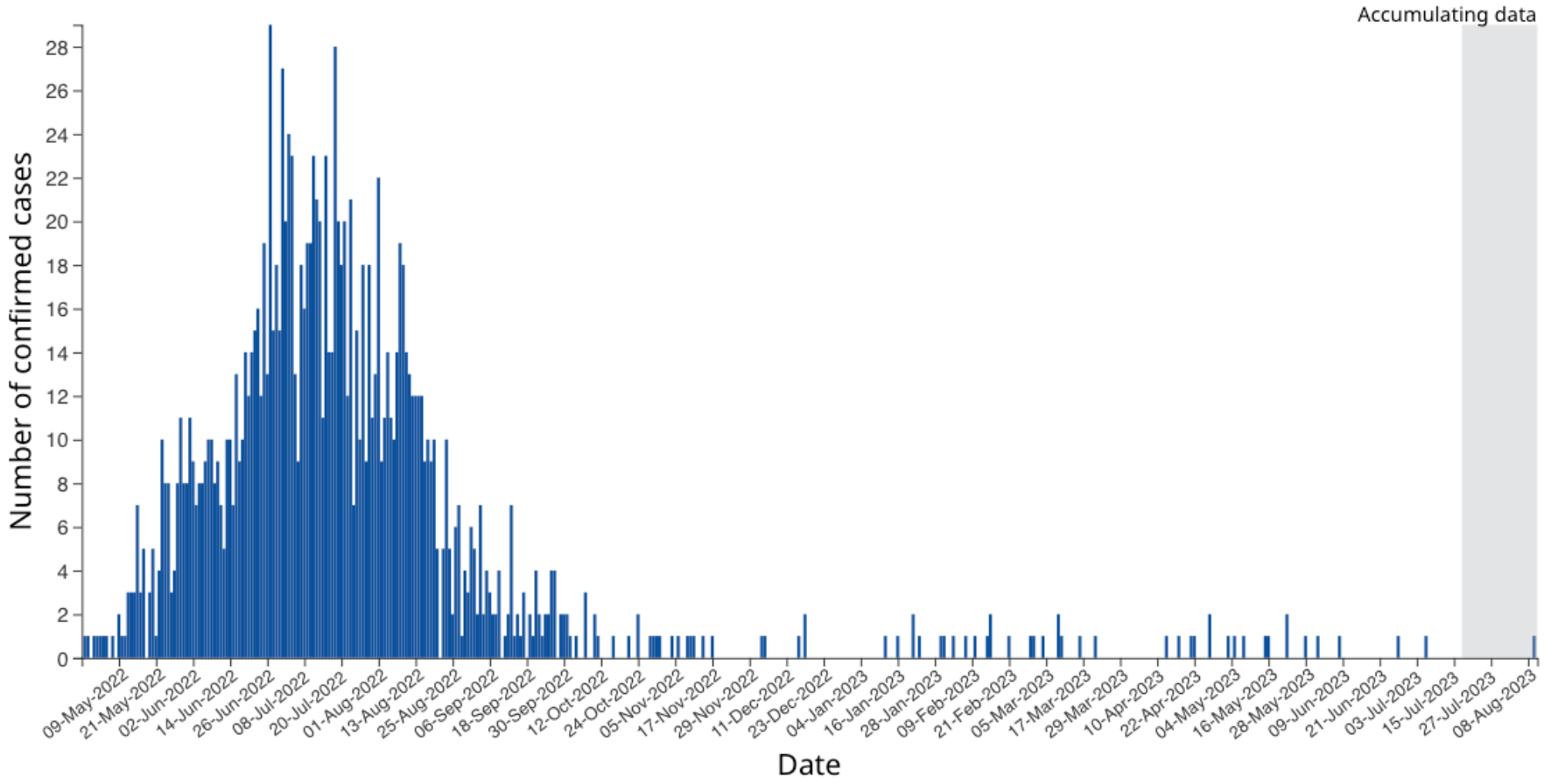

Poxviridae: mpox

- Virus is endemic in small mammals in West and Central Africa
  - Rope and sun squirrels, dormice, giant-pouched rats.
  - Often asymptomatic.
  - Threat to domestic species?
- Can infect **humans** (and NHP)
  - Person-to-person transmission occurs at a rate of 1-10%.
    - Mainly through direct, intimate contact.
- Disease in humans resembles smallpox
  - Clinical signs of smallpox + lymphadenopathy



Poxviridae: mpox



a) early vesicle, 3mm diameter



b) small pustule, 2mm diameter



c) umbilicated pustule, 3-4mm diameter



d) ulcerated lesion, 5mm diameter



e) crusting of a mature lesion



f) partially removed scab



Common pox viruses of ruminants

Table: SUBFAMILY: ***CHORDOPOXVIRINAE***

Genus	Virus	Geographical distribution
Orthopoxvirus	Vaccinia	Worldwide
	Smallpox (Variola major)	Eradicated worldwide in 1980
	Cowpox	Europe, Asia
	Camelpox	Asia, Africa
	Uasin Gishu disease	Eastern Africa
	Monkeypox	**West & Central Africa (imported to USA in April 2003)**
	Raccoonpox	**North America**
	Skunkpox	North America
Parapoxvirus	**Pseudocowpox (Milker's nodule)**	**Worldwide**
	Bovine papular stomatitis	**Worldwide**
	Orf (Contagious ecthyma)	**Worldwide**
	Sealpox	Worldwide
	Ausdyk disease	Africa, Asia
	Parapox of red deer (1987)	New Zealand
Capripoxvirus	Sheeppox	Africa, Asia
	Goatpox	Africa, Asia
	Lumpy skin disease (Neethling)	Africa
Avipoxvirus	**Fowlpox**	**Worldwide**
	Canarypox, Pigeonpox, Turkeypox, Quailpox, Lovebirdpox etc	
Leporipoxvirus	**Myxoma, Rabbit (Shope) fibroma**	**Americas, Europe, Australia**
	Hare fibroma	Europe
	Squirrel fibroma	North America
Suipoxvirus	**Swinepox**	**Worldwide**
Molluscipoxvirus	Molluscum contagiosum	Worldwide
Yatapoxvirus	Yabapox and tanapox	West Africa

Refer also to Table 7.1, pg 153, in Fenner's Veterinary Virology, 4th edition.

Poxviridae: Parapoxviruses

Orf

Bovine popular stomatitis

Pseudocowpox

Poxviridae: Parapoxviruses

Orf

Bovine popular stomatitis

Pseudocowpox

- Disease is usually most significant in younger animals (< 1 – 2 years)
- Zoonotic, particularly for people working with affected animals. Usually develop papular lesions on the hands.

Poxvidirae: Orf

Syn: Scabby mouth, Sore mouth. (Orf is an old English word meaning "rough").

- Important in young sheep (lambs 3-6 months) & goats; rarely in adults
- Infection occurs through contact with infected animals or contaminated soil, equipment, or feeding utensils.
- Lesions appear 2-4 days after exposure:
  - Lips & muzzle in lambs
  - Feet & udder in nursing ewes
  - Heal without scar formation.
- Causes no mortality, but lambs unable to suckle lose condition.



Poxviridae: Orf

- Recovered animals have a period of immunity (~ 1 year) but may then catch the virus again
  - Usually ↓ severity
- DDx:
  - Bluetongue virus
  - Foot and mouth disease virus
- Control:
  - Vaccination with virulent virus; administered by scarification of skin in 1-2 day-old lambs to 3-4 weeks old & ewes before lambing; induces short-lived immunity in lambs (~5 months)
- Virus is **zoonotic** (occupational disease)
  - Human disease is contagious pustular dermatitis.



Poxviridae: Pseudocowpox and BPSV

- These are two viruses of **cattle** that are in the same genus as Orf, and cause similar lesions in cattle.
- They have little clinical or economic significance, but occur commonly.
  - Lesions are mild.
- Pseudocowpox → teats
- Bovine papular stomatitis virus → muzzle, lips, oral mucosa, sometimes esophagus
- Zoonotic (similar to Orf)



http://coloradodisasterhelp.colostate.edu/prefair/disease/dz/Bovine%20Papular%20Stomatitis.html



Swinepox

Swinepox

- Associated with poor sanitation
  - Still occurs worldwide.
  - Rarely seen in commercial production.
- Disease is most significant in pigs 3-6 weeks old.
- Mechanically transmitted by hog louse (Hematopinus suis)

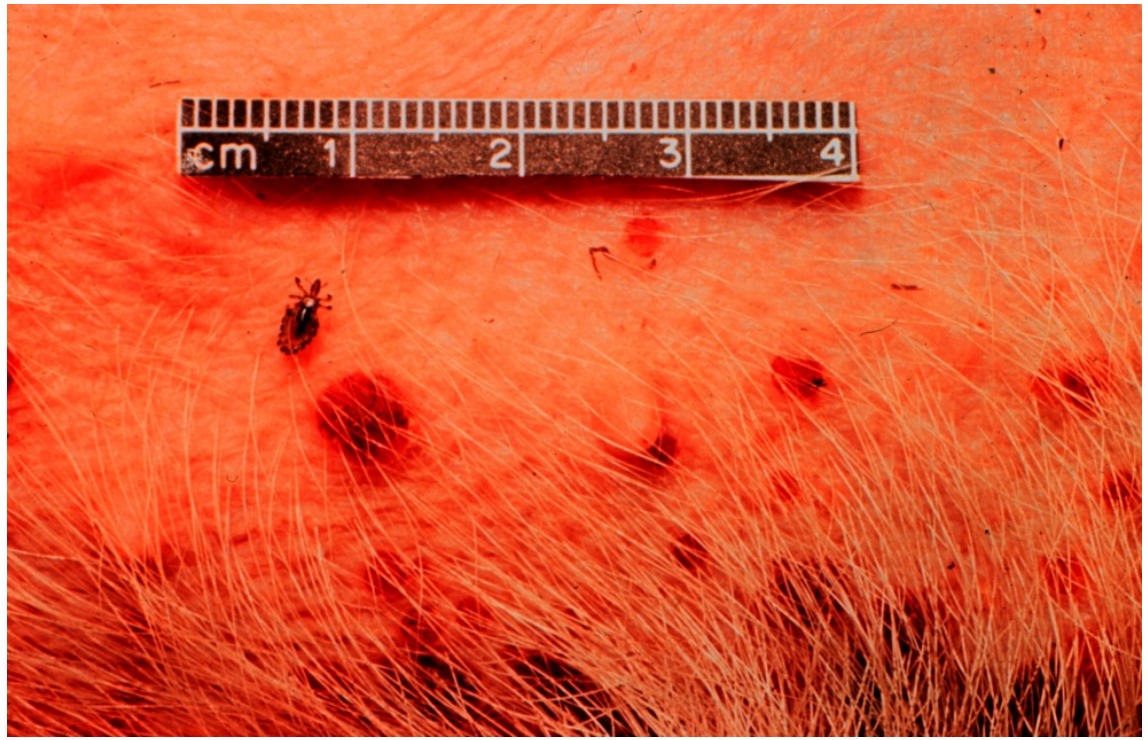

Skin: swine pox and *Hematopinus suis*

Swinepox: clinical signs, diagnosis, and control

- Lesions occur on belly & legs
  - Disappear without scar in 3 weeks
  - Successive crops of lesions at different stages of development may occur on the same animal.
- May have fever, anorexia
- Diagnosis: clinical signs/lesions are more or less pathognomonic
- Control of the virus is accomplished via control of the vector (louse)



Swinepox

- Lesions occur on belly & legs
  - Disappear without scar in 3 weeks
  - Successive crops of lesions at different stages of development may occur on the same animal.
- Diagnosis: clinical signs/lesions are more or less pathognomonic
- Control of the virus is accomplished via control of the vector (louse)





Avipoxviruses

Avipoxvirus

- Genus that contains 232+ species of virus that infect a wide range of birds (poultry and wild birds)

- Viruses recovered from various species of birds are given names pertaining to their respective host species, such as fowlpox (chickens), canarypox, turkeypox, pigeonpox, magpiepox, etc.
  - Exhibit a substantial degree of host-range specificity, especially those from wild birds.
  - The entire host-range of most of these viruses remains to be accurately determined.

- Mechanical transmission by arthropods, especially mosquitoes, provides a mechanism for transfer of the viruses between different species of birds.

- Fowlpox is a very important disease of chickens and turkeys.

Poxviridae: fowlpox

Occurs in two forms:

1. Cutaneous
2. Wet/Diphtheritic

Fowlpox

1 Cutaneous

- Most common
- Transmitted by arthropods or mechanical transmission to damaged skin
- Small papules on combs, wattles, and around the beak (less commonly on legs or cloaca)
- Rarely fatal
- May ↓ egg production



Fowlpox

1 Cutaneous

- Most common
- Transmitted by arthropods or mechanical transmission to damaged skin
- Small papules on combs, wattles, and around the beak (less commonly on legs or cloaca)
- Rarely fatal
- May ↓ egg production



Fowlpox

2 Wet/Diphtheritic

- Infection via droplets
- Infection of the MMs of the oropharynx, esophagus, ± trachea
- Can form a necrotic pseudomembrane which can asphyxiate the animal
- ↑ ↑ mortality



Fowlpox: diagnosis and control

- DDx:
  - Cutaneous form is fairly characteristic.
  - “Wet” form – ILT, IB, vit A deficiency
- Diagnosis:
  - History, gross + histo
  - PCR is available for confirmation
- Control:
  - Virus within scabs is very resistant to desiccation
  - Various vaccines are available and are used in flocks where disease is endemic

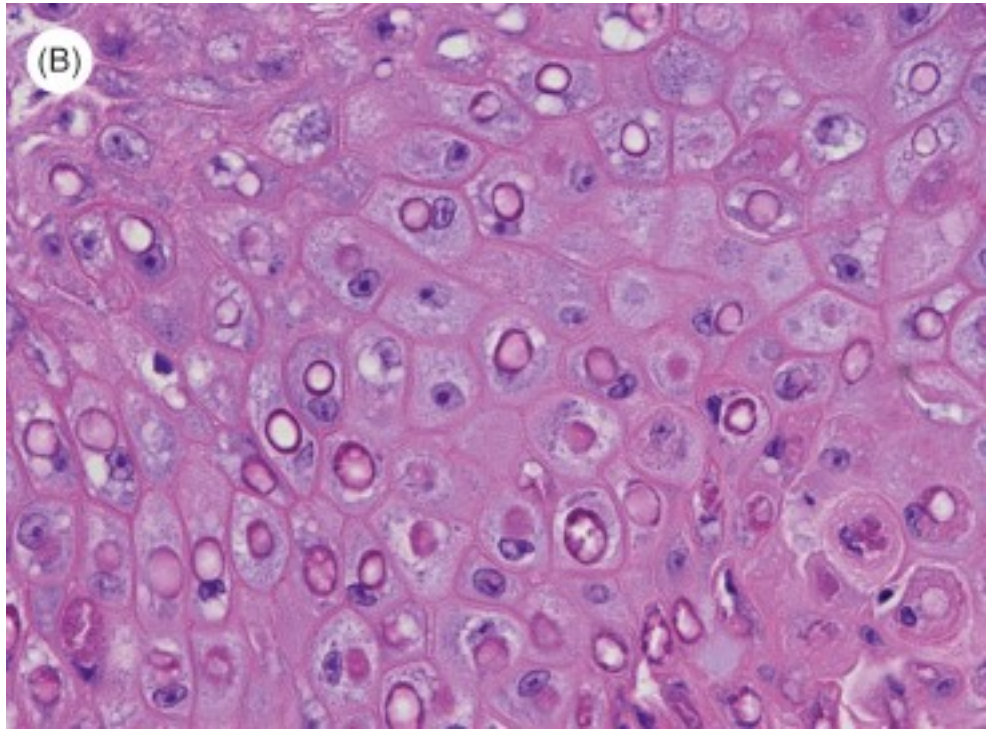



Capripoxviruses

Capripoxvirus

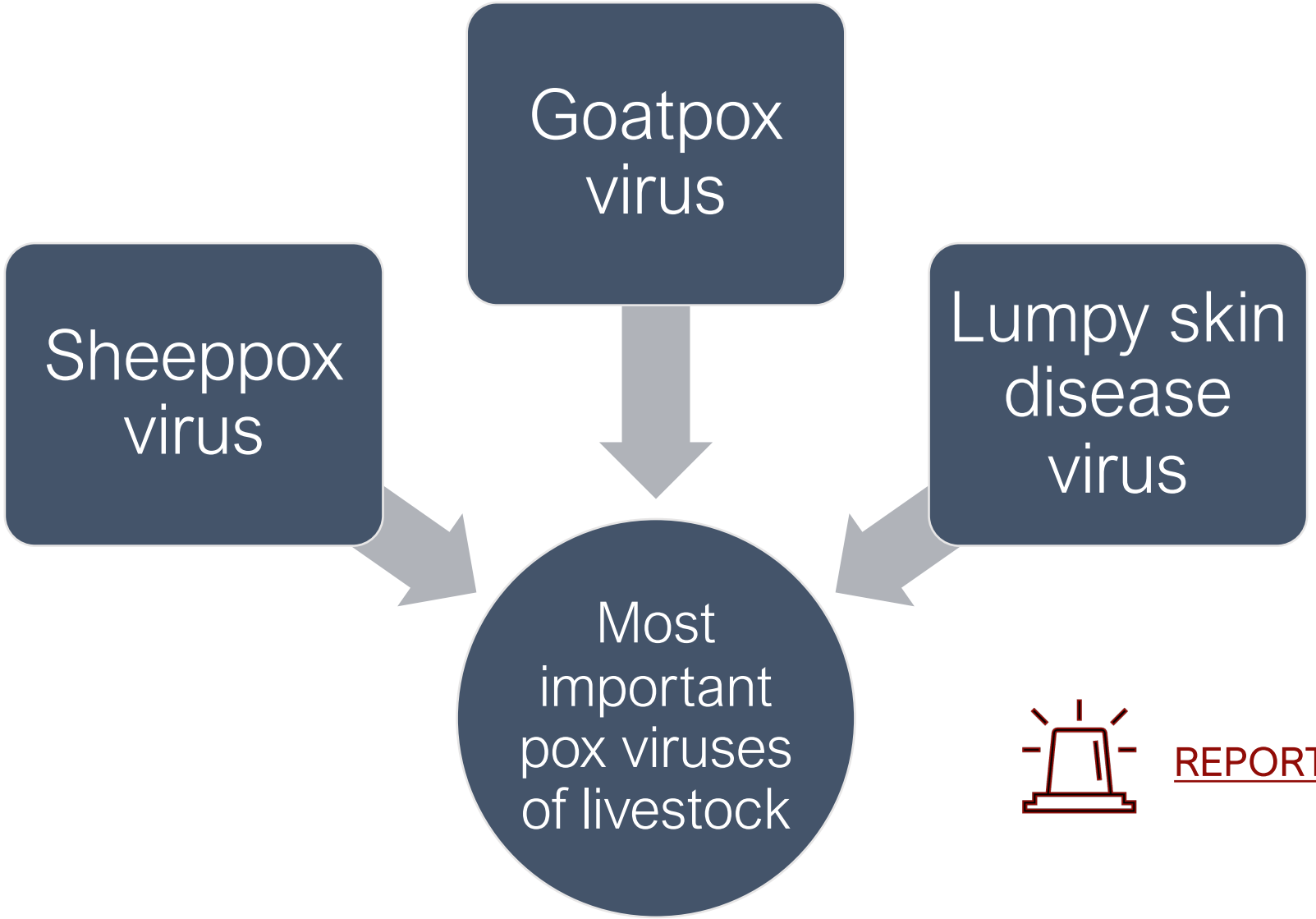

REPORTABLE

Capripoxvirus

- The causative agents, sheeppox, goatpox, and lumpy skin disease viruses, are indistinguishable by conventional serological tests.
- Infection with one of these viruses induces cross-protection to other capripoxviruses.
- Lumpy skin disease virus infects only cattle
- Some strains of sheeppox and goatpox viruses infect both sheep and goats.
  - Most isolates of sheeppox and goatpox viruses cause more severe disease in either sheep or goats and only mild or asymptomatic infection in the other species.

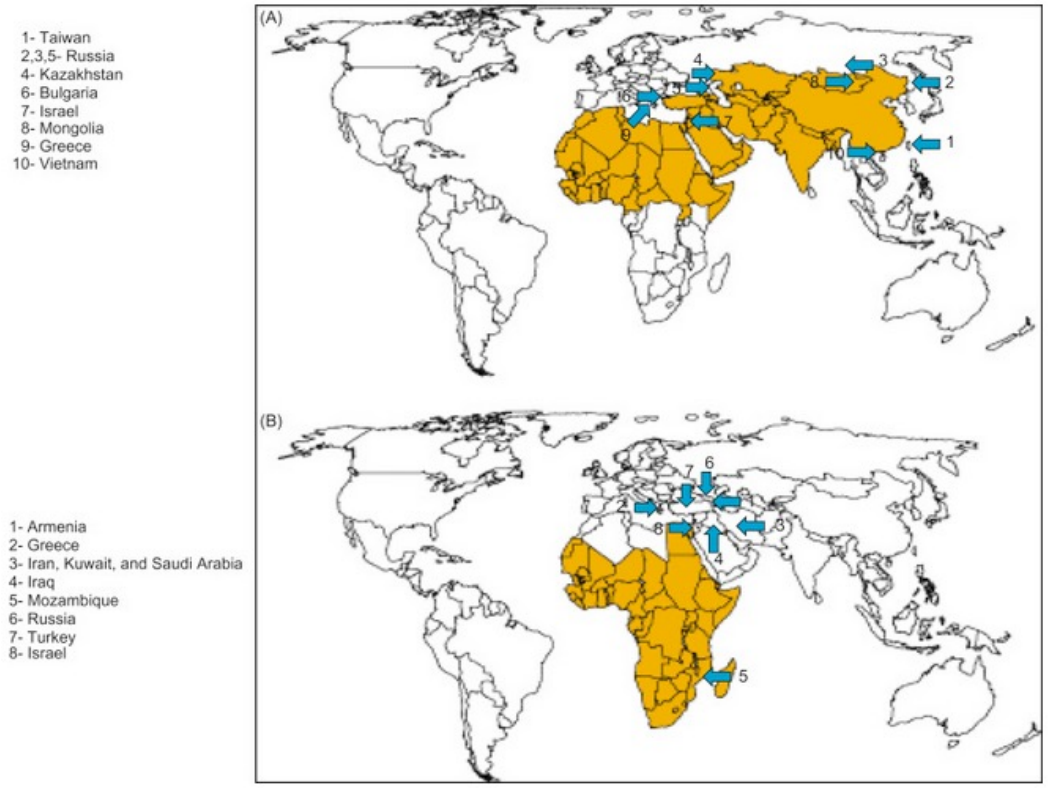

Download : Download full-size image

Figure 7.4. Map showing likely global distribution of (A) sheeppox and goatpox, and (B) lumpy skin disease (LSD) viruses. Recent outbreaks are marked with arrows.

Adapted from Babiuk, S.L., Bowden, T.R., Boyle, S.B., Wallace, D.B., Kitchen, R.P., 2008. Capripoxviruses: an emerging worldwide threat to sheep, goats and cattle. Transbound. Emerg. Dis. 55, 263–272, with permission.

Capripoxvirus: transmission

- Direct contact with skin abrasions
- Aerosol/droplet (likely important in outbreaks)
- Biting insects (particularly LSDV)



Sheep & goatpox: pathogenesis

- Systemic disease
- Monocytes spread virus
- Proliferative lesions, similar to the classical pocks of the skin, can be seen in internal organs:
  - Lungs
  - Forestomachs
  - Liver
  - Kidneys

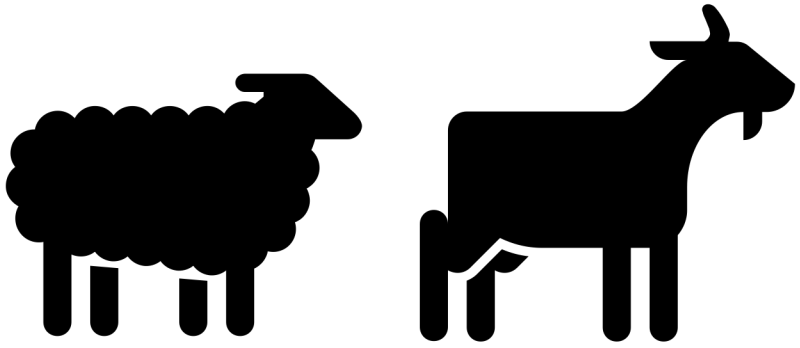

Capripoxvirus: clinical signs

- Young or immunocompromised → ↑ severity
- ↑ temp, RR
- ↑ lacrimation
- Characteristic pock lesions
- ↓ milk production
- ↑ abortion rates
- ↓ weight gain
- ↑ susceptibility to secondary bacterial infections
- ↑ ↑ ↑ mortality.

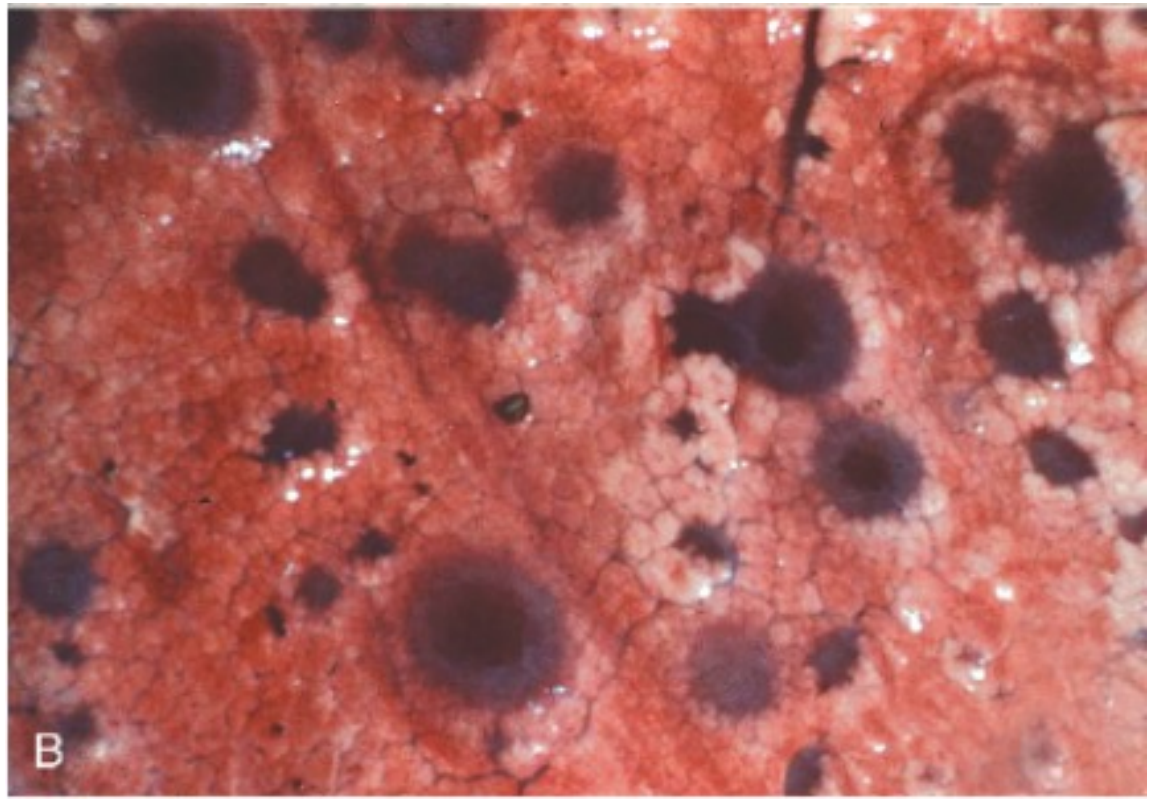

Proliferating epithelial cells (bronchiolar), necrotic epithelium, and inflammation form these characteristic plum-coloured circular lesions in the lung

LSDV: clinical signs

- ↑ morbidity, ↓ mortality
- Fever
- Lymphadenopathy
- Characteristic, wide-spread pock lesions
- Slow healing – cattle may remain debilitated for months
  - Economic importance is due to prolonged production loss

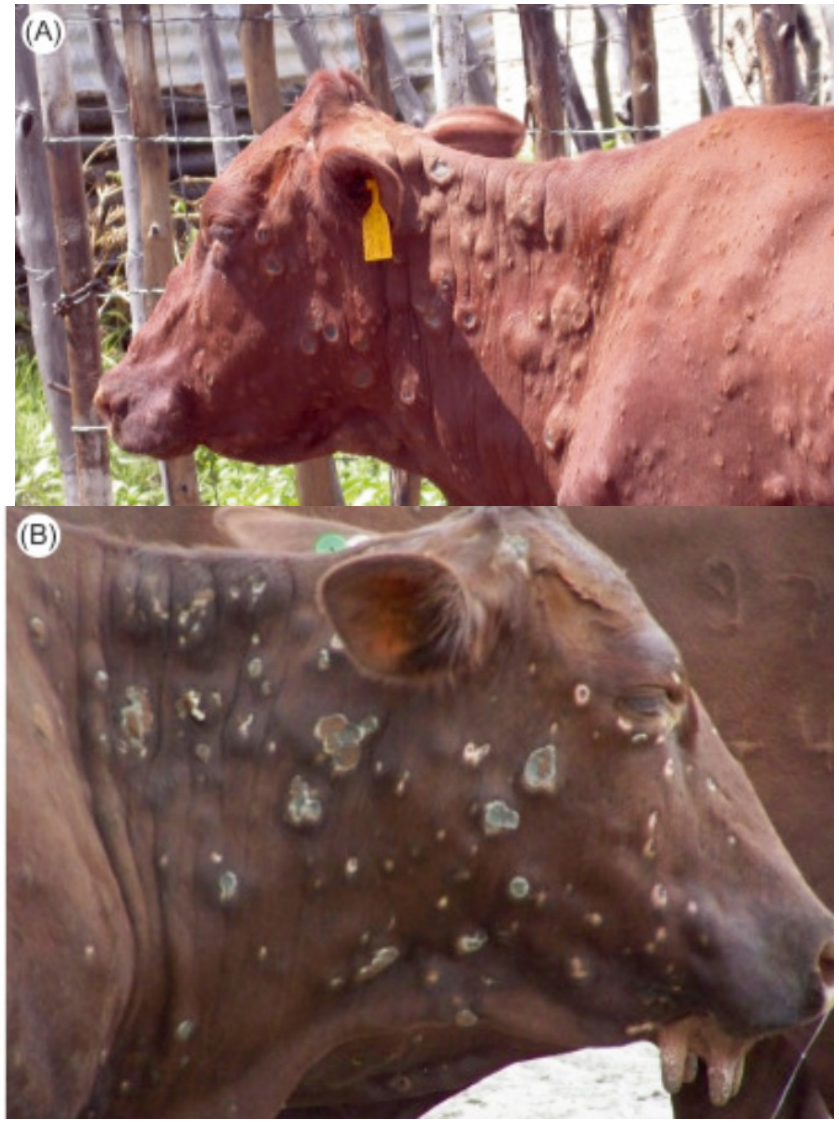

Capripoxvirus: diagnosis & control

- Clinical signs are relatively characteristic
- PCR, virus isolation are commonly used.

- Immunity is lifelong
- Vaccines are available

- These diseases are reportable and control in North America is through vigilance and reporting.

BONUS POX!!





BONUS POX!!



