



This Photo by Unknown Author is licensed under CC BY-SA



This Photo by Unknown Author is licensed under CC BY-SA

Systematic Virology, Lecture 13

Adenoviridae, Papillomaviridae, Polyomaviridae



Adenoviridae

https://www.urdogs.com/wp-content/uploads/2016/04/Picture1.png

Adenoviridae: general

Size	70 – 90 nm
Morphology	Naked
	Icosahedral, penton fibers
Genome	linear, dsDNA
Site of Replication	• Nucleus
Properties	• Release by cell lysis • Intranuclear inclusions • Stable in the environment

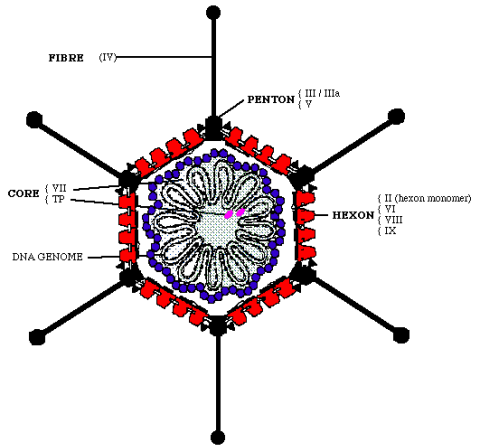

Adenoviridae: important diseases

Canine adenovirus 1	Infectious canine hepatitis
Canine adenovirus 2	Part of canine respiratory disease complex
Turkey hemorrhagic enteritis virus	Hemorrhagic enteritis

CAV1: transmission and pathogenesis

- Widely distributed
- Usually affects young puppies
- Transmission: horizontal
  - Urine, feces, and saliva
  - Oral, nasopharyngeal, and conjunctiva
  - Dog-to-dog, fomites
- Replication in tonsillar crypts → LN → lymph → blood → lungs, liver, kidney, spleen, eye, endothelium → necrosis and hemorrhage

CAV1: clinical signs

- Peracute: found dead

- Acute:
  - Fever
  - Vomiting
  - Anorexia
  - Jaundice
  - Petechia
  - Clotting abnormalities

recovery → Transient anterior uveitis and corneal edema (25 % of dogs)

- Mild disease
  - Non-specific clinical signs

recovery

CAV1: clinical signs

- Marked cloudiness and blue-tinge to the cornea, consistent with corneal edema.
- Recovery usually ~ 3 weeks post-infection
- Occasionally, glaucoma may result

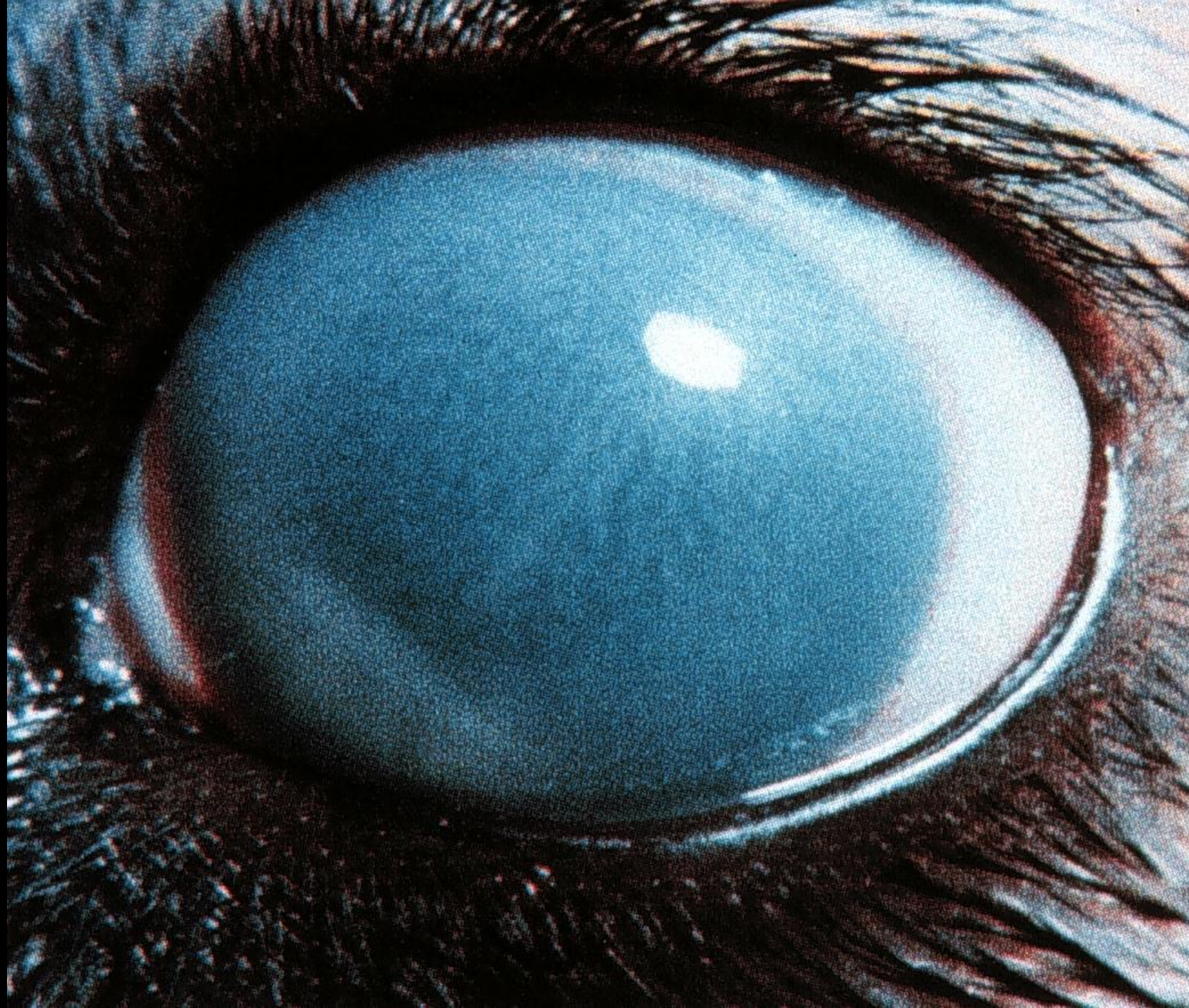

CAV1: lesions

- Intranuclear inclusion bodies.
- Centrilobular to panlobular necrosis would be widespread in this liver.

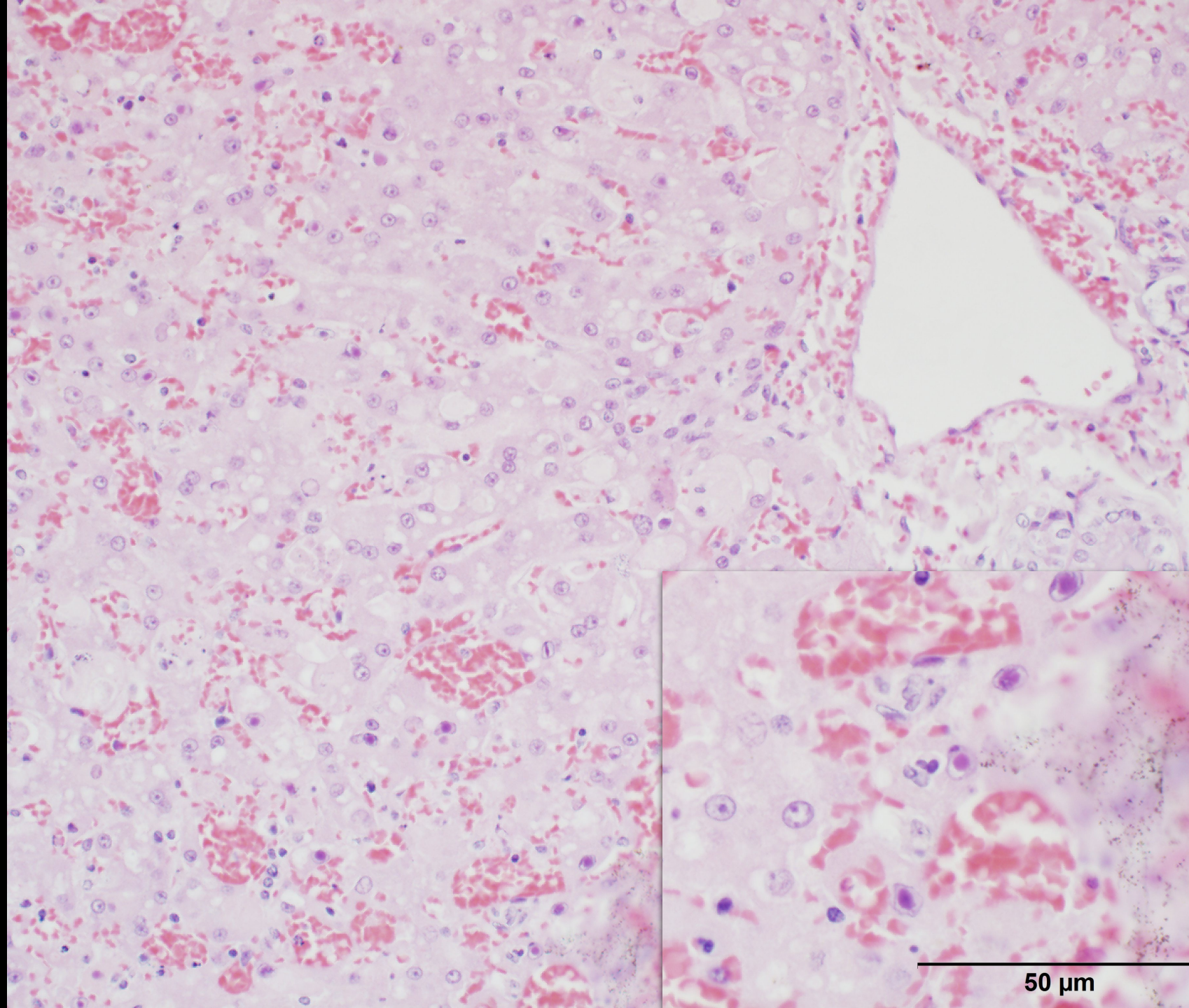

CAV1: diagnosis and control

- PCR (urine is a good choice)

- Vaccination is highly effective, and has mostly reduced the incidence of this disease to 0 where it is practiced.

- Vaccine uses MLV **CAV-2 (NOT CAV-1)**
  - CAV-1 vaccines can result in corneal edema (~ 1 % of dogs)
  - Watch out for maternal Ab

Canine adenovirus 2

- Causes respiratory disease
- Part of “Kennel cough” syndrome/complex
- Occurs in dogs of all ages
- CAV-2 vaccine protects against CAV-2 (to some degree)



Viral infection is usually complicated by bacterial infection, hence the purulent nasal discharge



Papillomaviridae

Papillomaviridae: general

Size	55 nm
Morphology	Naked
	Icosahedral
Genome	circular, dsDNA
Site of Replication	• Nucleus
Properties	• Highly host specific • Tissue restricted (usually squamous epithelium) • Released by cell lysis • Form benign tumours

Papillomaviridae: general

- Highly host** and tissue specific
  - Differentiated squamous epithelium
  - *** Exception: BPV-1, 2 → equine sarcoids*
  - *** Exception: BPV-14 → feline sarcoids*

- Cause characteristic benign epithelial growths – papillomas and warts

- Most frequent in young (and immunosuppressed) animals

Papillomaviridae: general

- Horizontal transmission:
  - Close contact
  - Contaminated fomites (halters, milking equipment, etc)

- Virus infects basal cells of dermal layer (through skin abrasions & cuts) causing benign outgrowths of cells called papillomas or warts

- Encode a protein that prevents cells from leaving the cell cycle.

- With time, cytotoxic T-cell immune response develops and papillomas regress
  - Animals becomes highly immune to the infecting **strain** of papillomavirus

- Diagnosis is based on characteristic lesions, but can be confirmed with PCR on affected tissue

- Control and vaccination generally not necessary, the disease is usually self-limiting.

Papillomaviridae: important viruses

- Bovine papillomaviruses 1-10
  - Most commonly infected species
- Equine sarcoids
- Canine papillomavirus 1-4

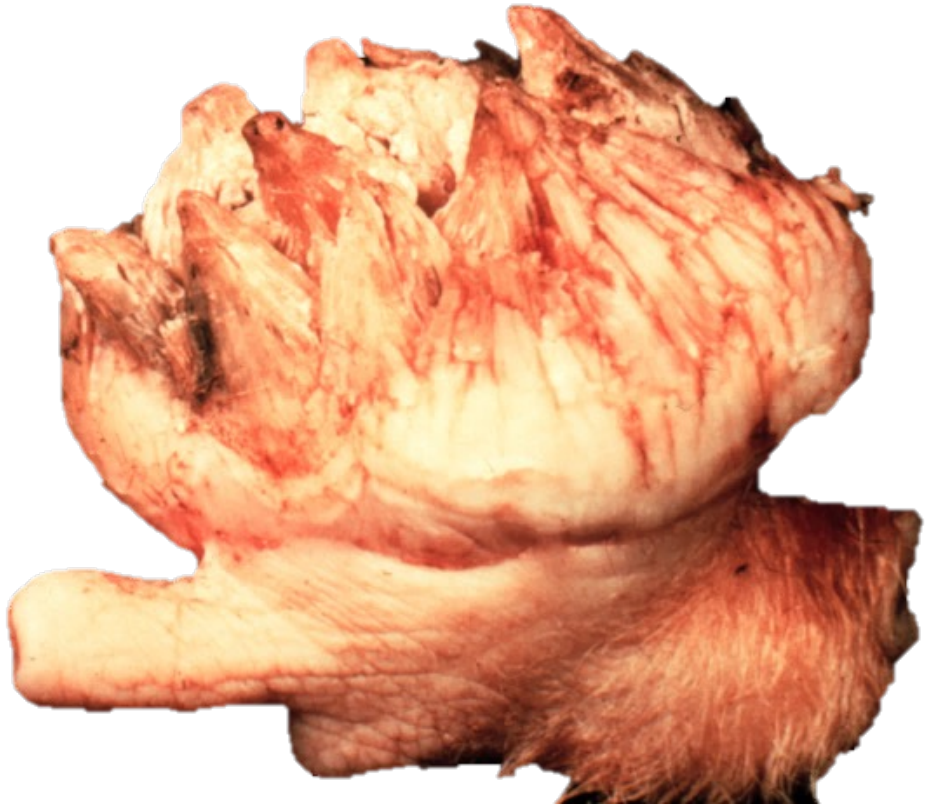

BPV

- Ten different strains
- BPV-1, -2: Fibropapillomas in cattle
  - Induces fibroblast proliferation (“fibro”)
  - AND equine sarcoids

- Infection of BPV-4 and consumption of bracken fern → squamous cell carcinoma in the GI tract (esophagus, forestomachs)

- BPV 3, 6, 9, 10 → papillomas

BPV





Equine sarcoids and BPV

- One of the most common tumour of horses

- Are essentially fibrosarcomas
  - Locally invasive
  - Metastasis is uncommon to rare

- Are strongly associated with BPV-1 and -2
  - DNA from BPV-1 and -2 can be detected in most sarcoids



Equine sarcoids and BPV

- No breed, sex, age predilections
- May be single or multiple
  - 1/3 of horses will have multiple tumours at the time of initial diagnosis
- Head, neck, ventral abdomen/thorax
- Initially slow growing in the dermis/epidermis, but gradually extends into the subQ.
- Early, wide excision provides best therapy, but can be very challenging.



BPV and equine sarcoids



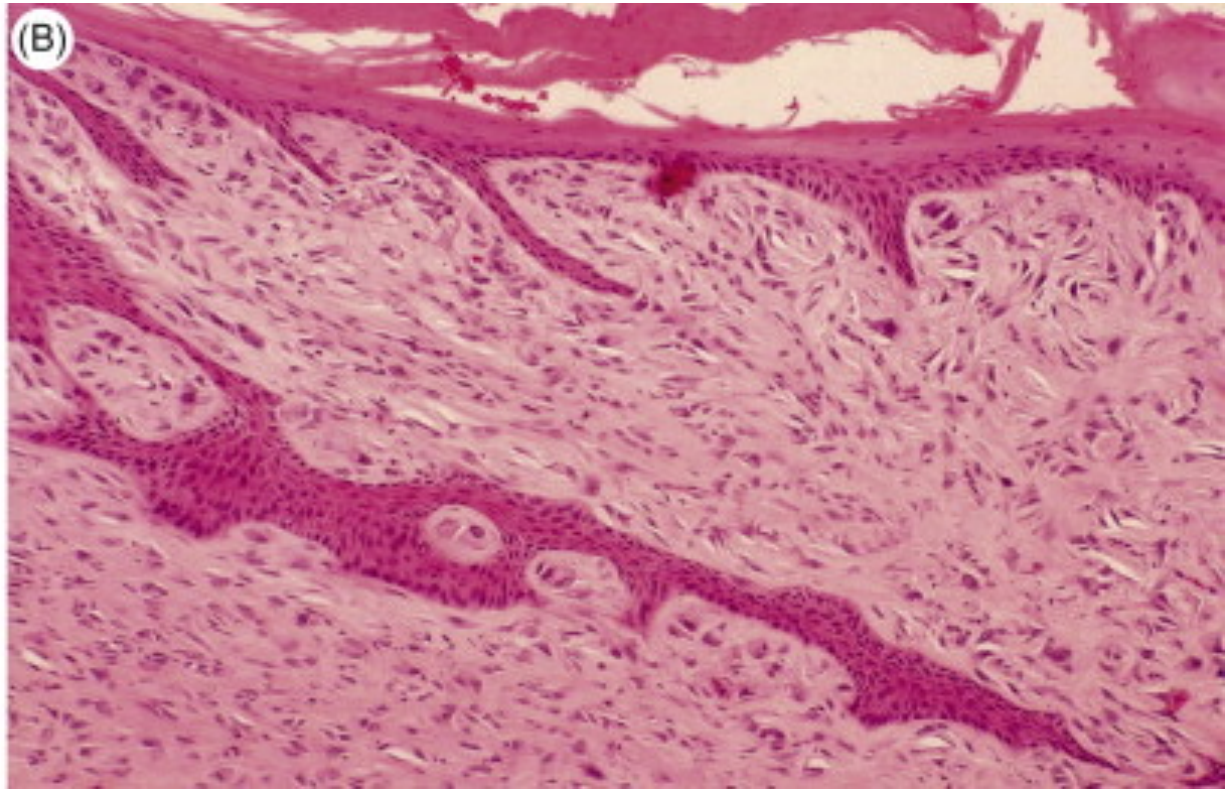

Canine papillomavirus

- Up to seven papillomaviruses from dogs characterized to date

- Cause papillomas in dogs:
  - Canine oral papillomas (occur on mucosal surface of mouth & lips),
  - Cutaneous pigmented plaques (rare & occur on head, eyelids, & feet)

- Canine oral papillomas:
  - Common in young dogs
  - Highly contagious
  - Benign & spontaneously regress after 1-5 months, with immunity to re-infection
  - Can be surgically removed if interfering with mastication, swallowing or for aesthetic reasons.
    - Sometimes removal of one causes the others to regress spontaneously.



Canine papillomavirus



Polyomaviridae



This Photo by Unknown Author is licensed under CC BY-SA

Polyomaviridae: general

Size	40-45 nm
Morphology	Naked
	Icosahedral
Genome	circular, dsDNA
Site of Replication	• Nucleus
Properties	• In mammals: highly host specific • In birds: broad host range • Very similar to papillomaviridae • Released by cell lysis • Most are non-pathogenic

Avian polyomaviruses (formerly known as budgerigar fledgling disease virus) are the only one we will discuss

Avian polyomaviruses

- Host range: fledgling budgerigars, other parrots.
- Disease is important in breeding aviaries; may cause up to 30-80% mortality in fledgling budgerigars ≤ 21 days old.
- Affected birds have full crops (crop stasis), die acutely (i.e., die suddenly with minimal clinical warning) and show abdominal distension & reddening of skin.
  - Differential diagnosis for proventricular dilatation disease (PDD) (avian bornavirus disease)
- Surviving birds are stunted & lack normal feather development
  - Differential diagnosis for psittacine beak and feather disease
- Gross: multifocal hemorrhage (petechial and ecchymotic, on various organs), hepatomegaly, renomegaly, ascites, hydropericardium.
- Histo: hepatic necrosis, intranuclear inclusions in cells of various organs.